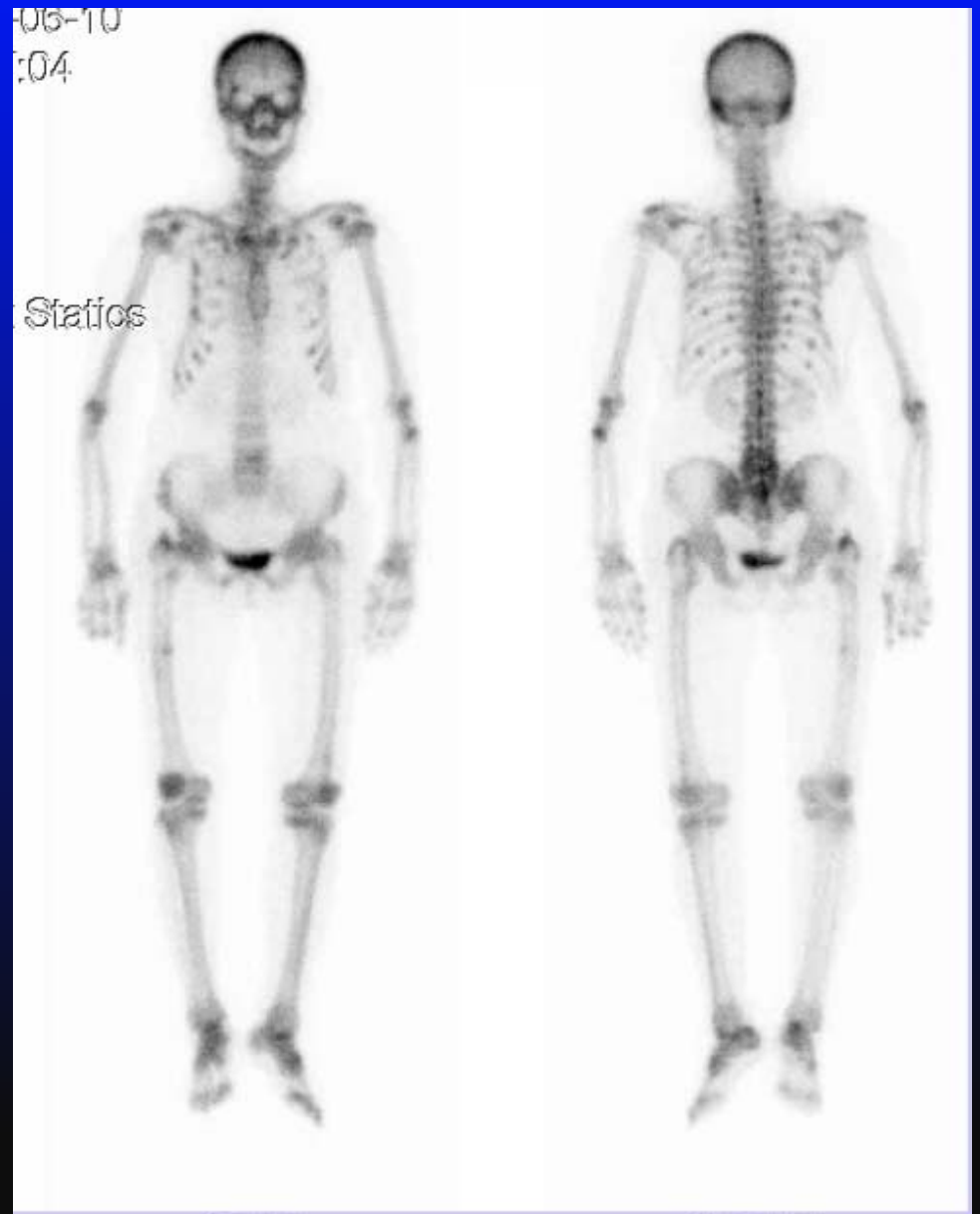


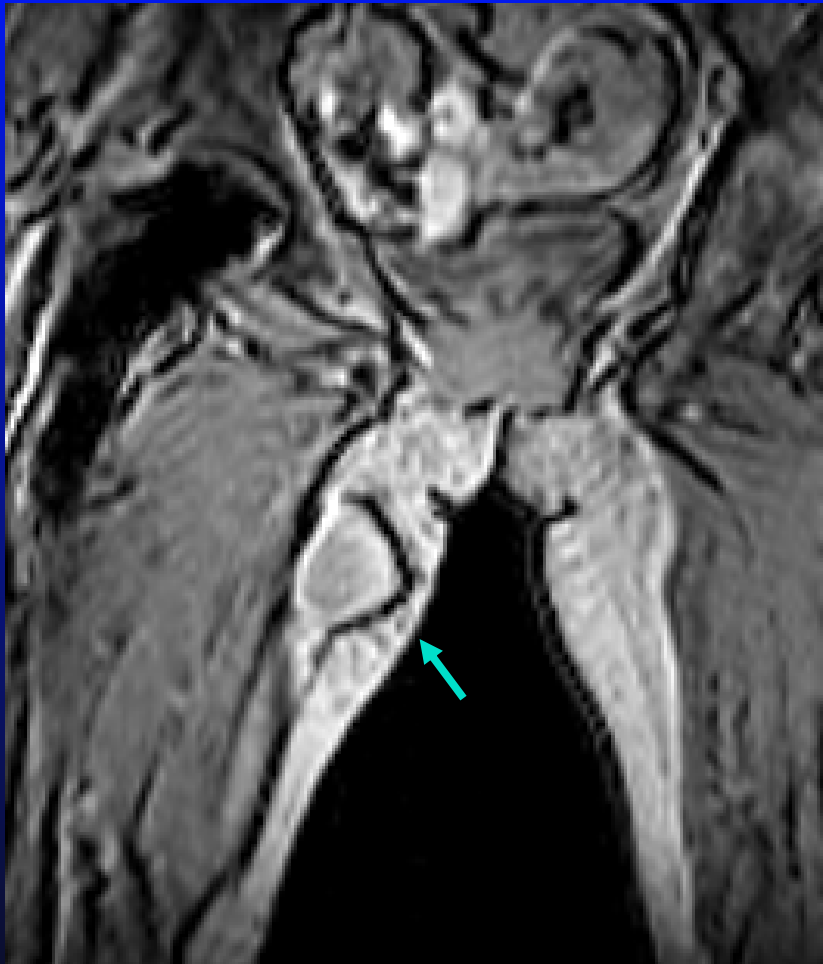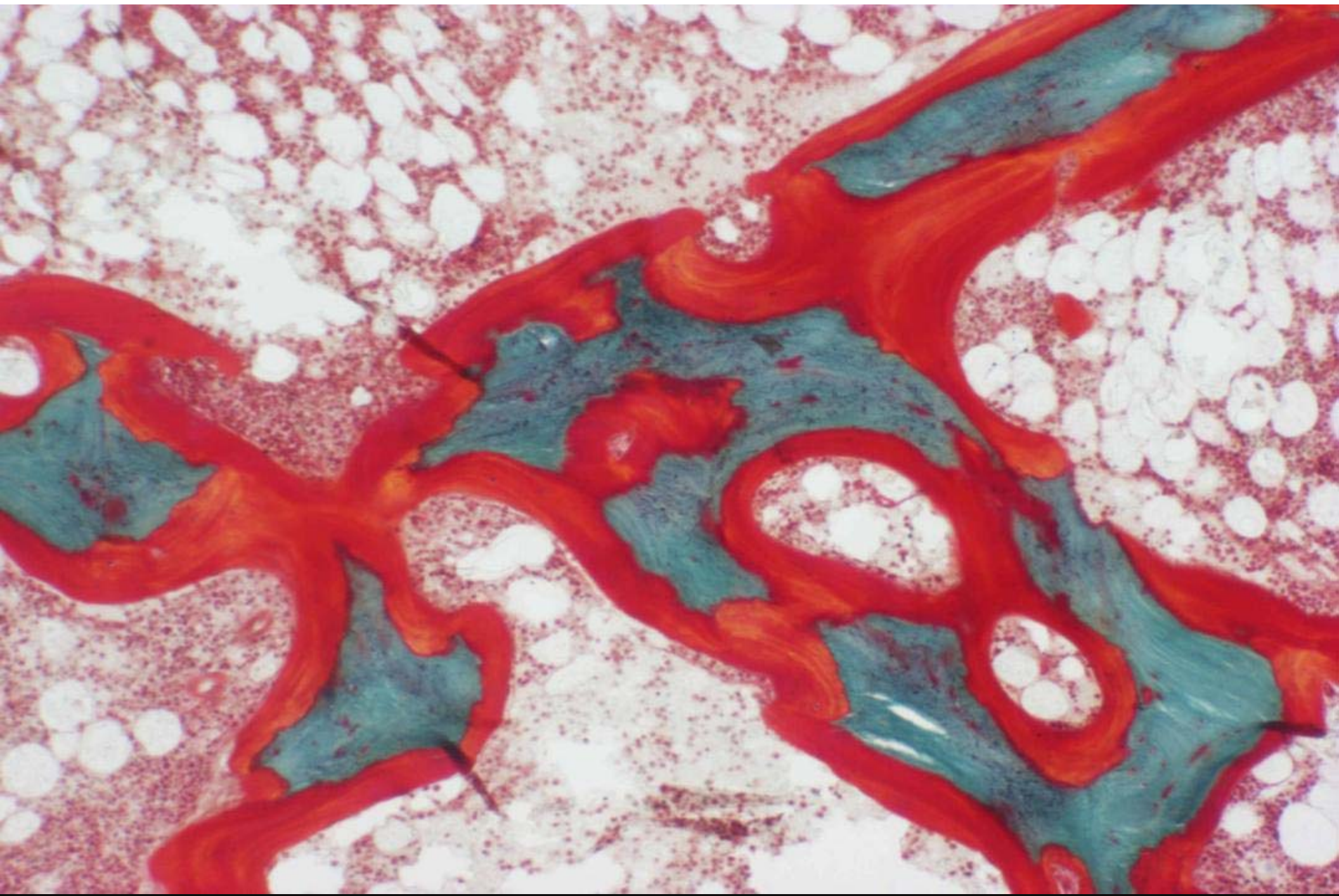


السلام عليكم

Case #3

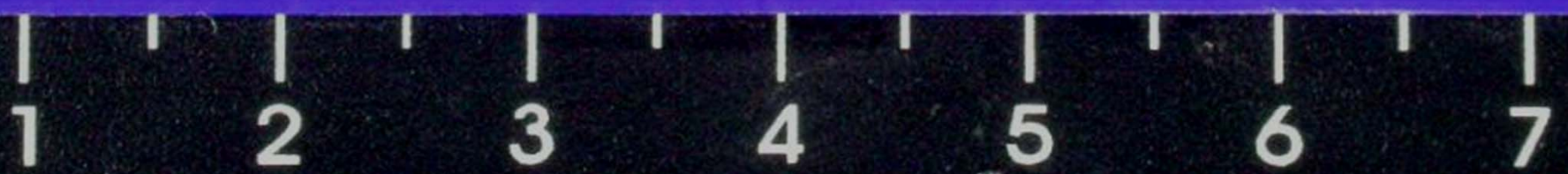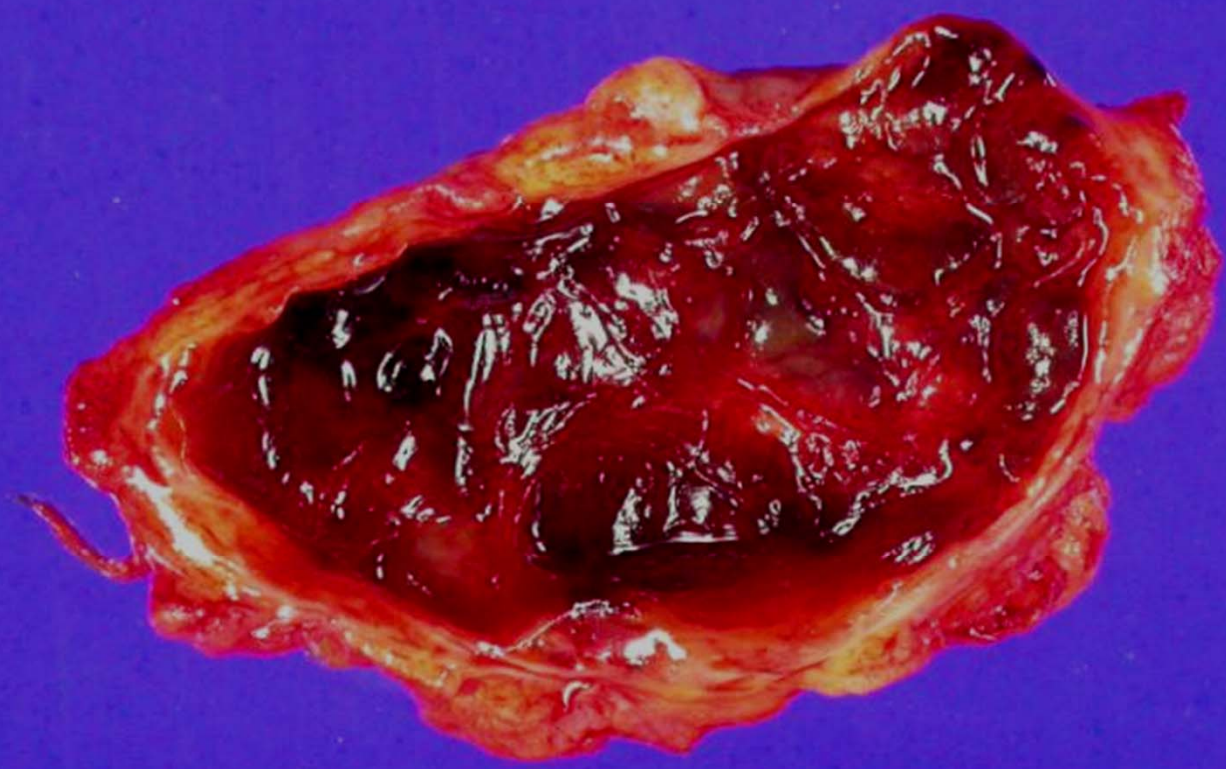
- 68yo, Female
- Generalized systemic bone pain



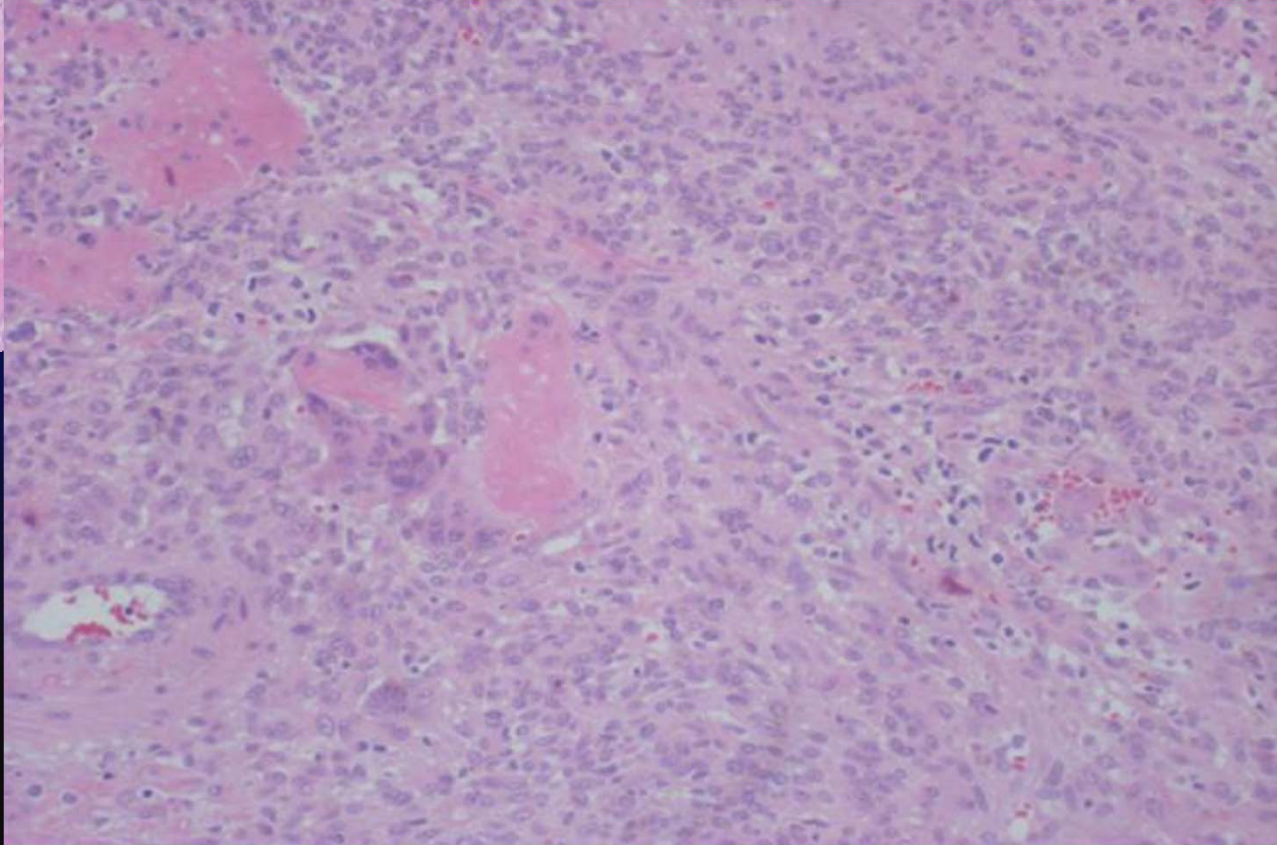
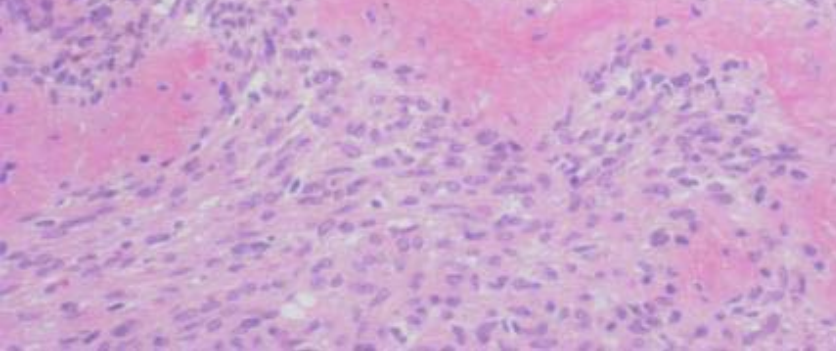
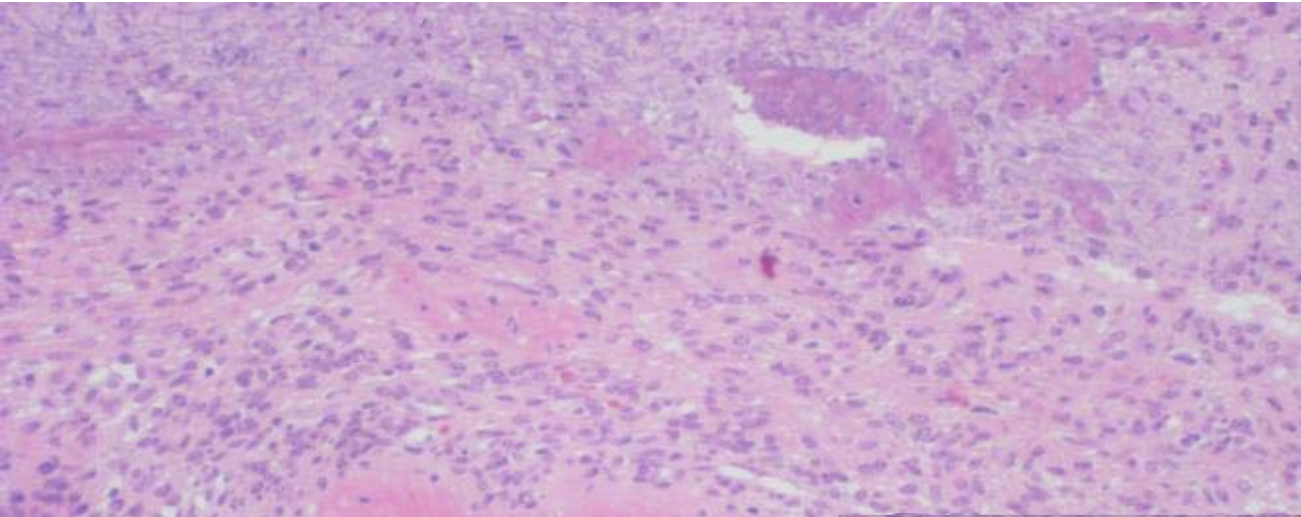


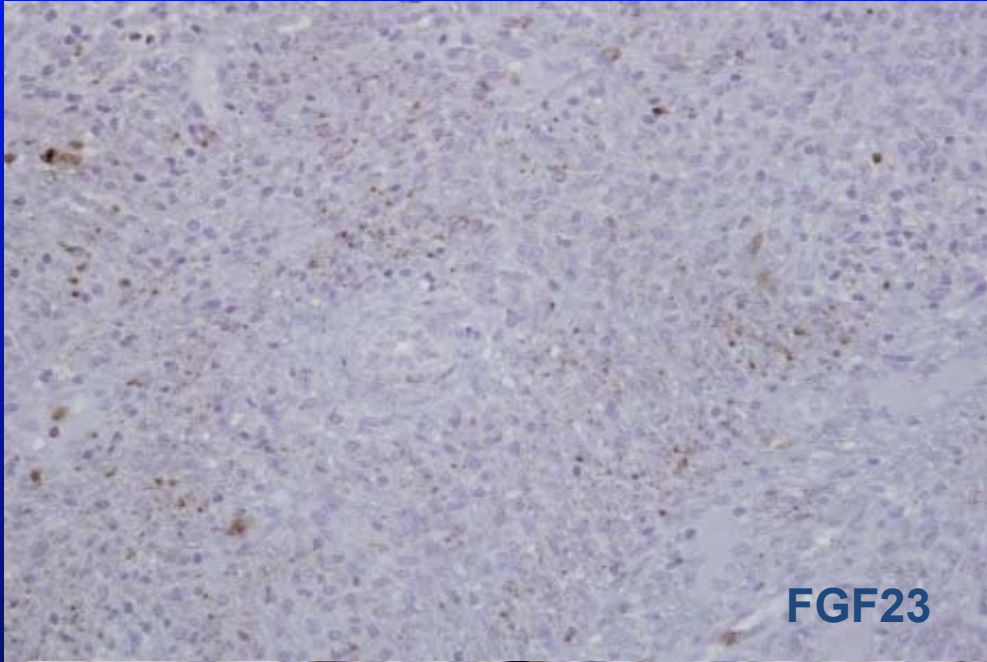
Bone Histomorphometry

- OV/BV: 149.33 % (1.54)
- OS/BS: 98.93 % (16.9)
- MS/BS: 0.53 % (8.3)
- MAR: 1.22 $\mu\text{m}/\text{day}$ (0.77)
- Aj.AR: 0.01 $\mu\text{m}/\text{day}$ (0.39)
- Mlt: 19254.48 days (17.9)
- Omt: 103.36 days (9.3)
- O.th: 125.86 μm (6.6) (Normal range)

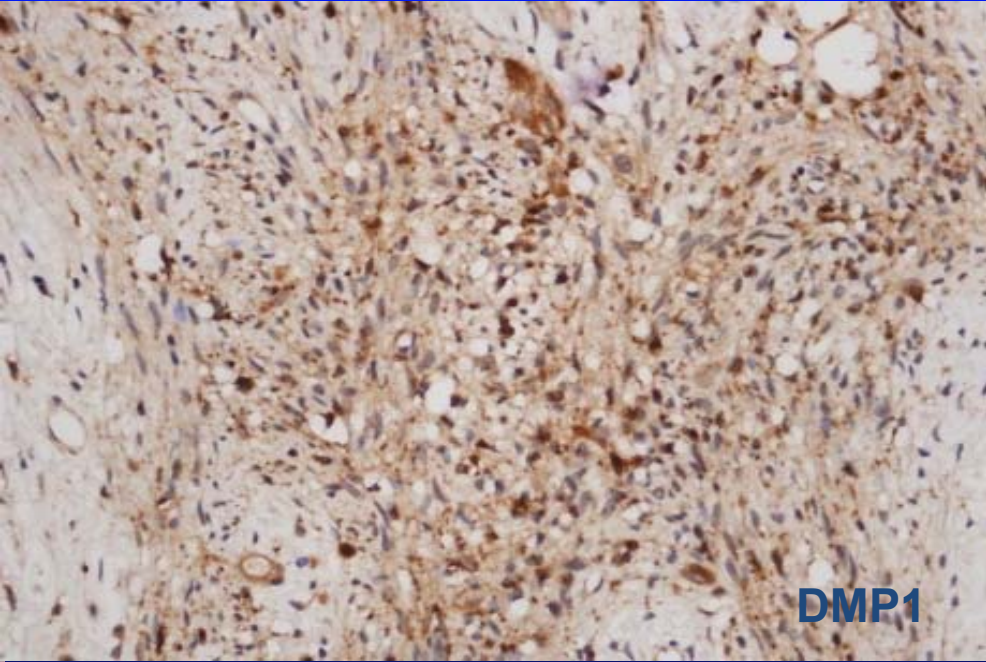


KYUNG HEE PATHOLOGY

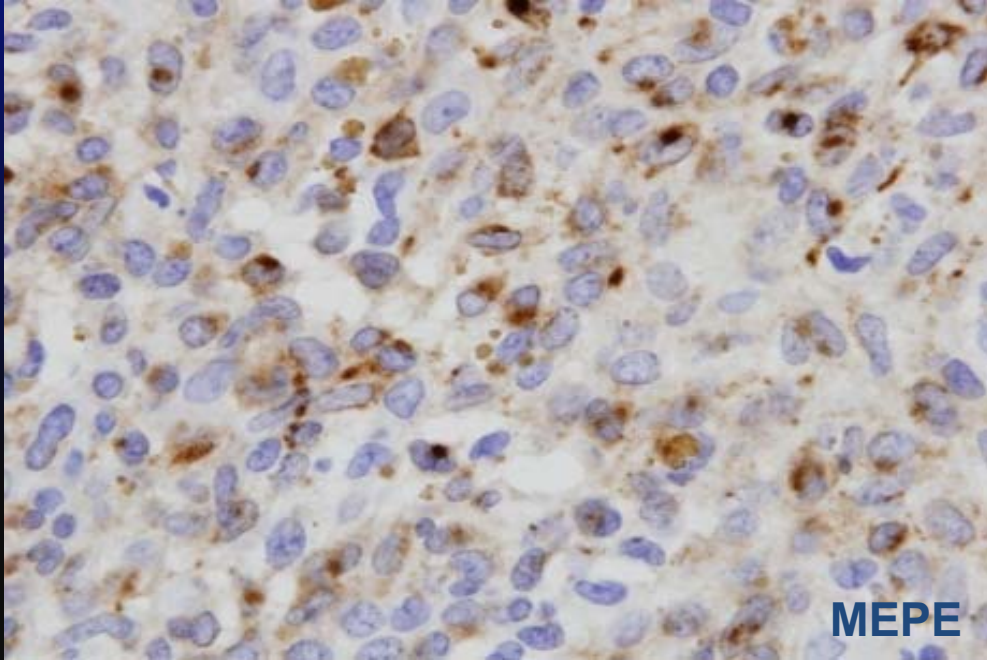




FGF23

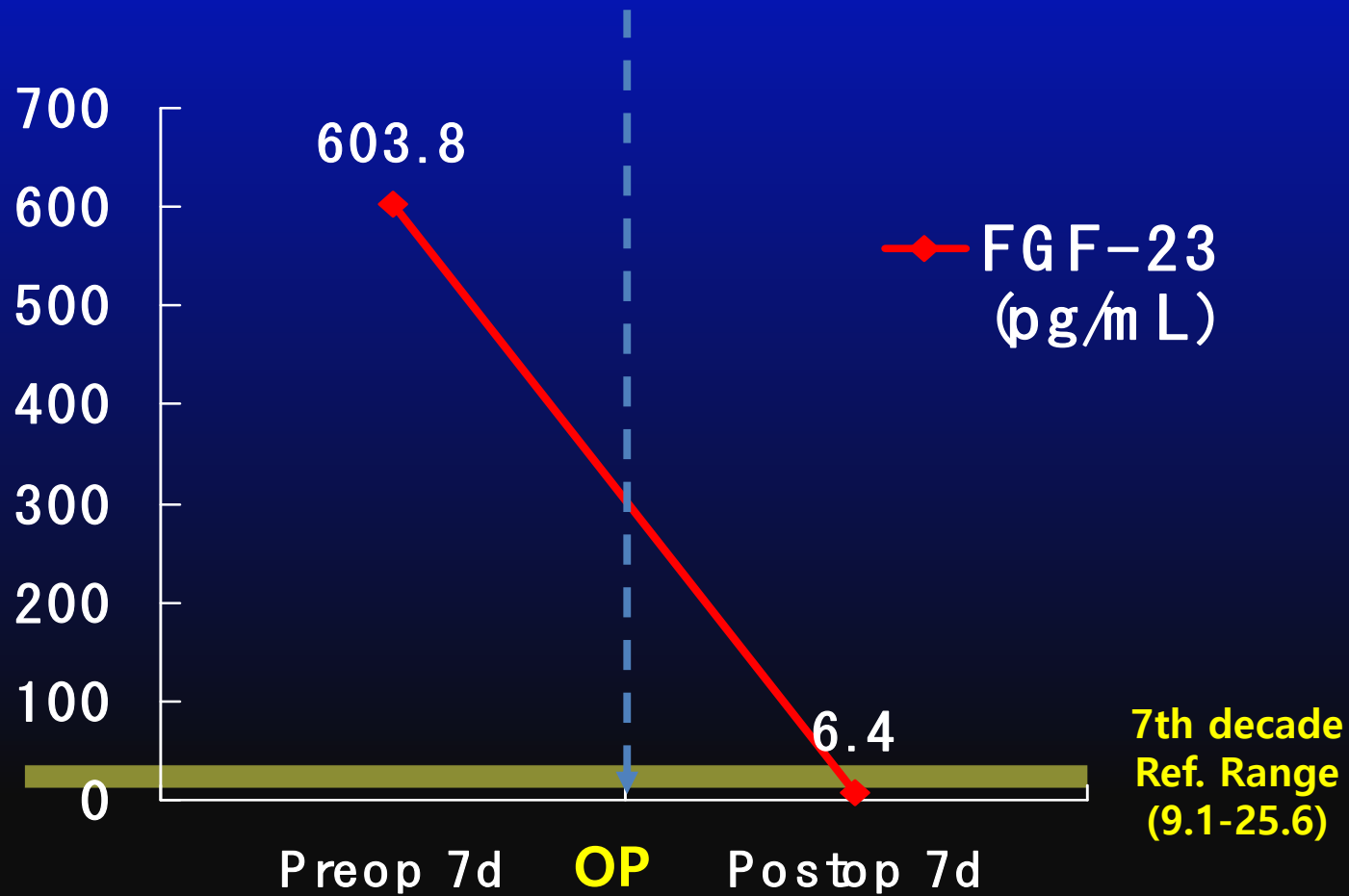


DMP1



MEPE

FGF-23 Protein in Serum



History


- 1947 McCance:

“Degenerate Osteoid tissue” –15 YO
Female, Femur

- 1959 Prader:


“Giant cell reparative granuloma of the
rib”

11 YO, Female, Cause and effect
relationship



Robert A. McCance

**(Dec. 9, 1898 -
Mar. 3, 1993)**



Andrea Prader


**(Dec. 23 1919-
Jun. 3, 2001)**

Definition of TIO

- Pt with Mesenchymal tumor & Osteomalacia

- Without

- Family History of Rickets
- Heavy Metal Poisoning
- Conditions leading to Fanconi syndrome



Biochemical Hallmarks

- Low serum phosphorus level (2.2 to 0.33 mg/dl)
- Increased renal phosphate leak and decreased tubular reabsorption (23 to 70 %)
- Elevated alkaline phosphatase activity (occasionally up to 1700 to 2300 IU)

Literature review

- Soft tissue tumors: 54 %
- Bone tumors: 29 %
- Epithelial tumors: 11 %
- Oral lesion: 3 %
- Others: 3 %

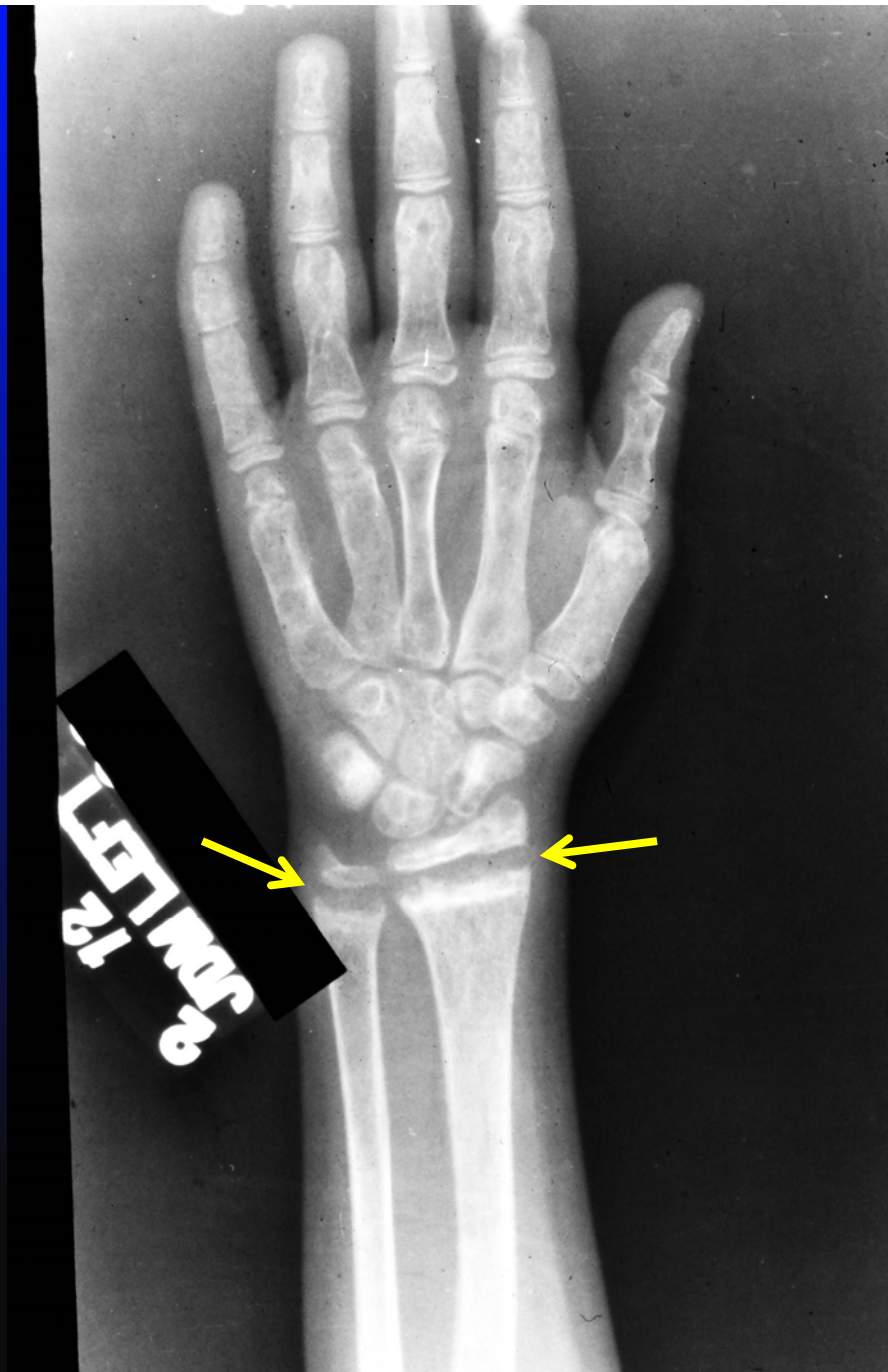
Soft tissue tumors

- Phosphaturic mesenchymal tumor:
- Hemangiopericytoma:
- Hemangioma:
- Neurofibromatosis
- Fibrous histiocyctoma
- Fibrosarcoma
- Glomangioma, vascular mesenchymoma, hemangioendothelioma, Synovial sarcoma, Malignant schwannoma,

Bone lesions

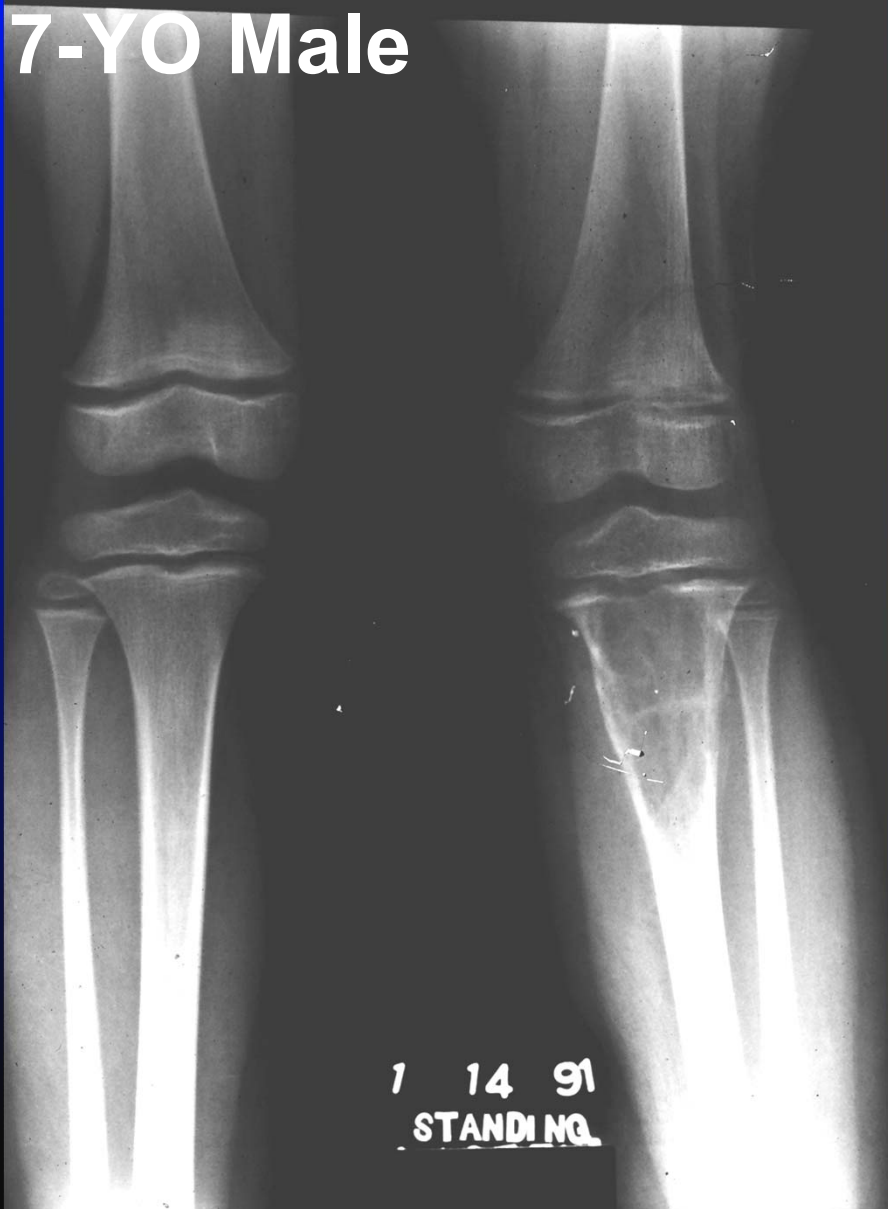
- Giant cell tumor 7
- Nonossifying fibroma 7
- Osteoblastoma 4
- Fibrous dysplasia (w/ polyostotic) 4
- Osteosarcoma 3
- Chondroblastoma 2
- Malig. Chondroblastoma 2
- Mesenchymal chondrosarcoma,
hemangiopericytoma
Hemangioma, CMF, PVNS, MFH,
Chondroma, Benign fibro-osseous
lesion

55-YO Female

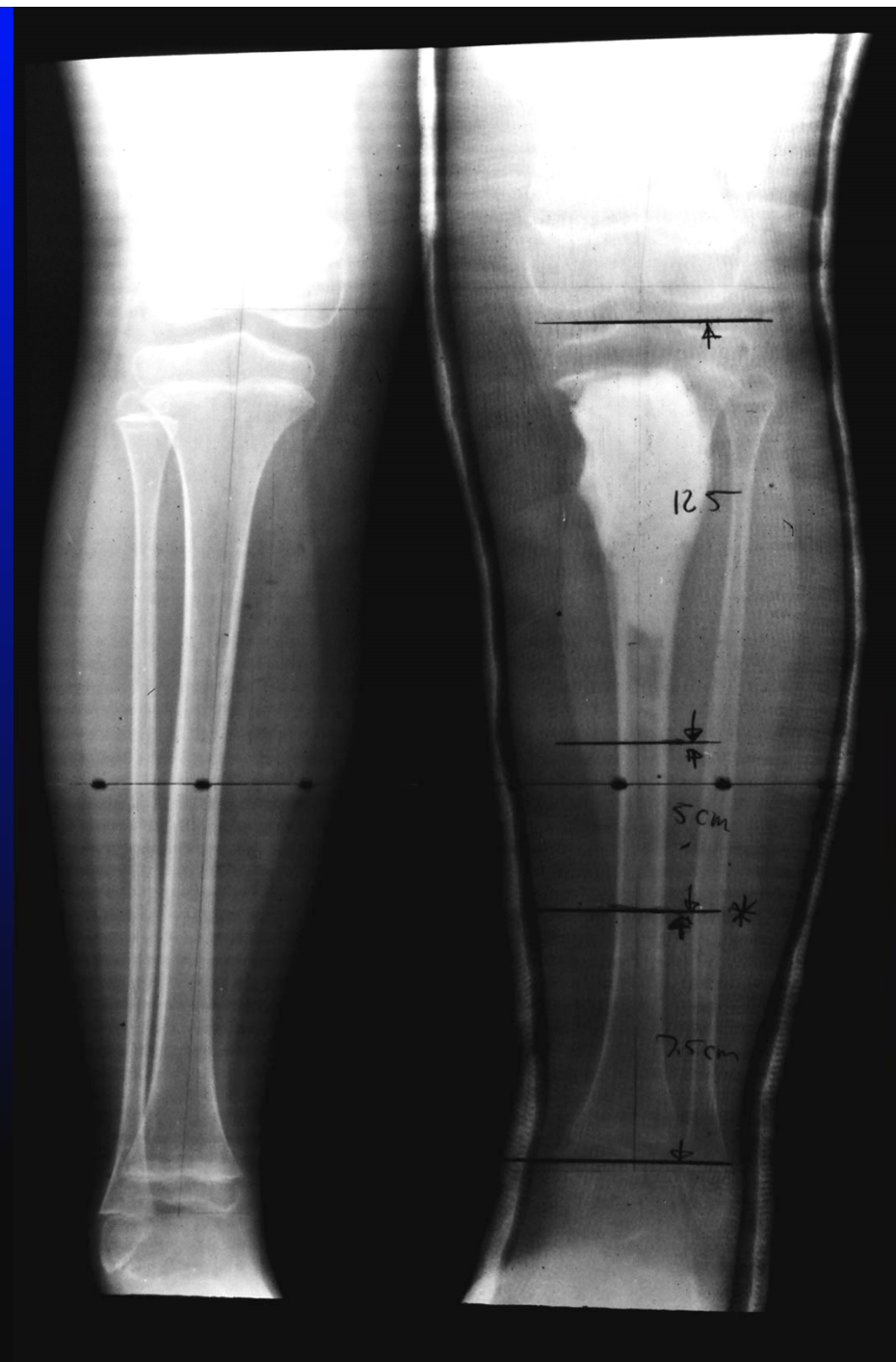


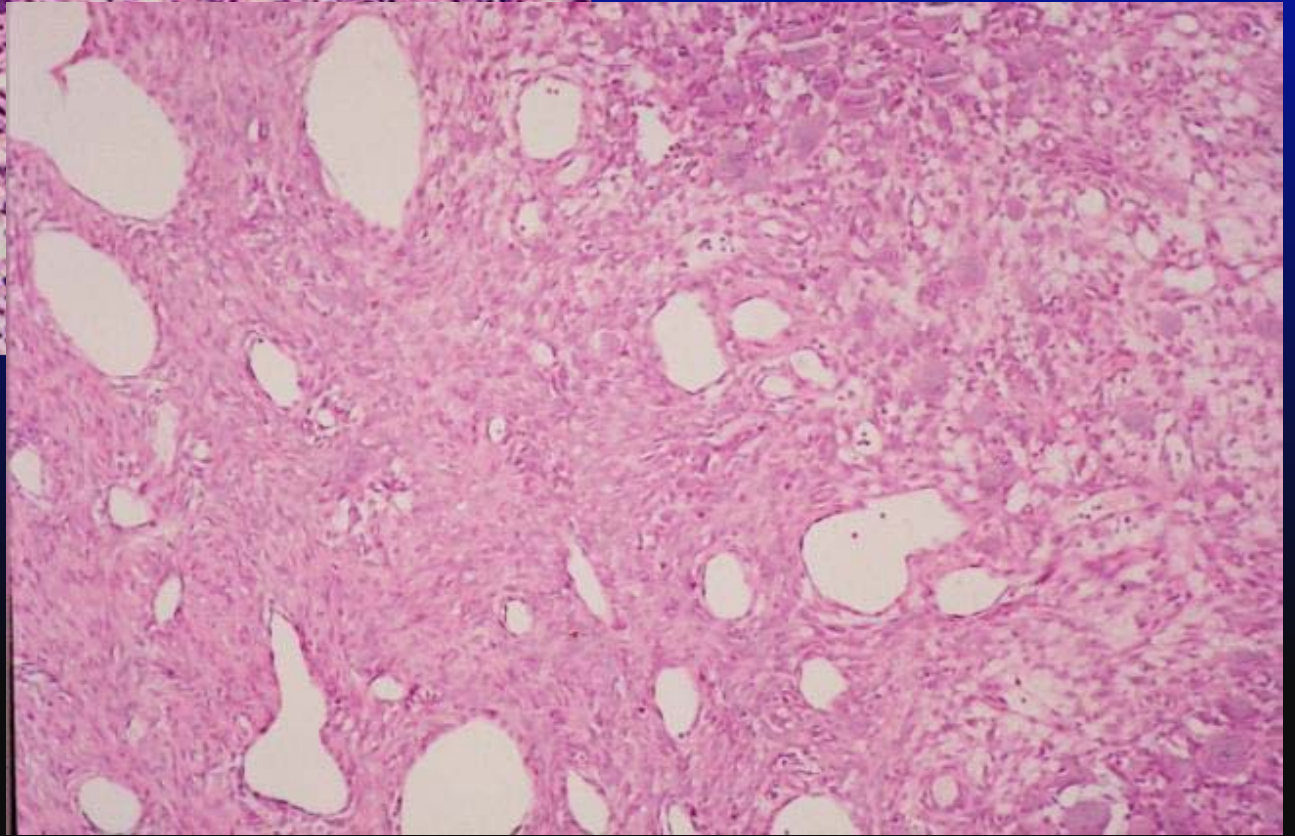
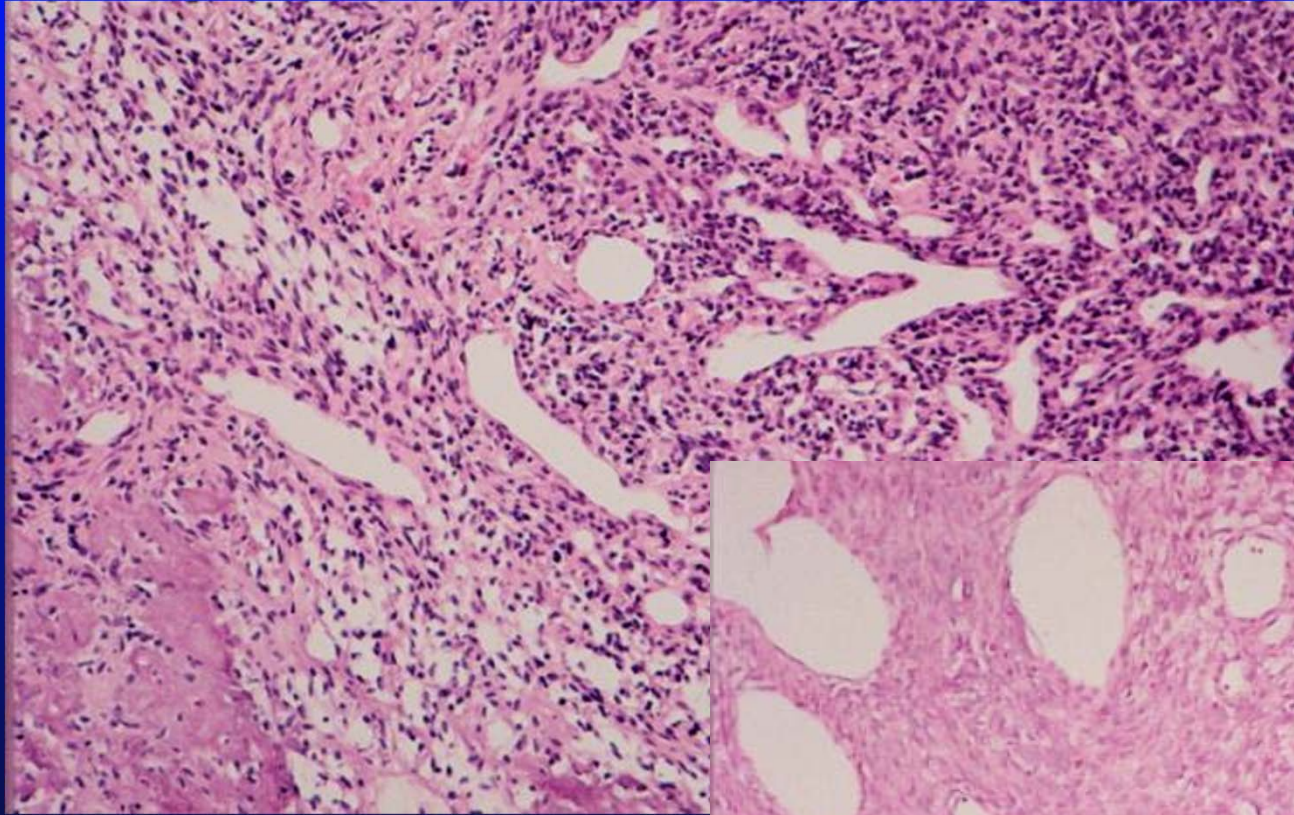
Park Yk, Unni KK; 1994

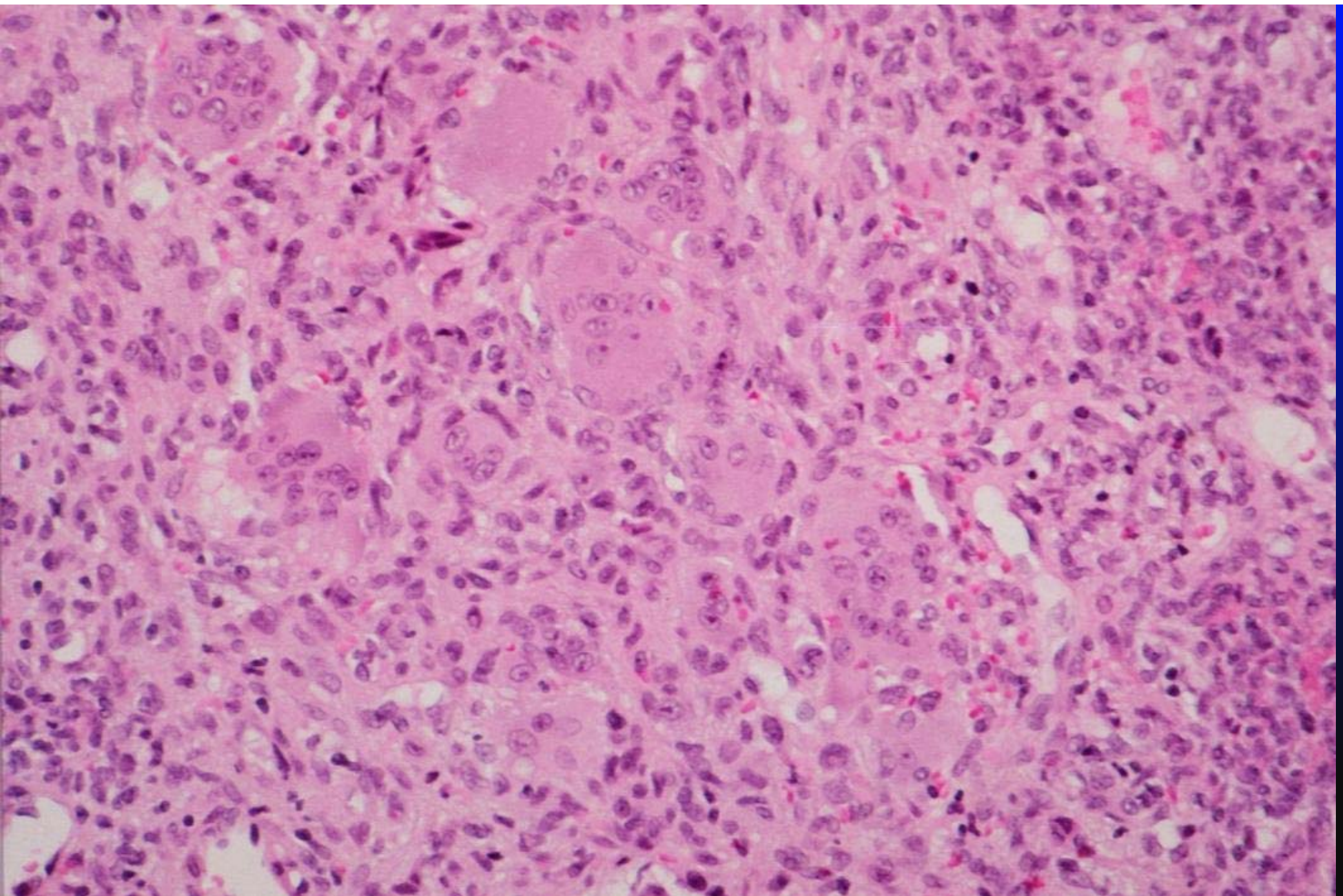
7-YO Male

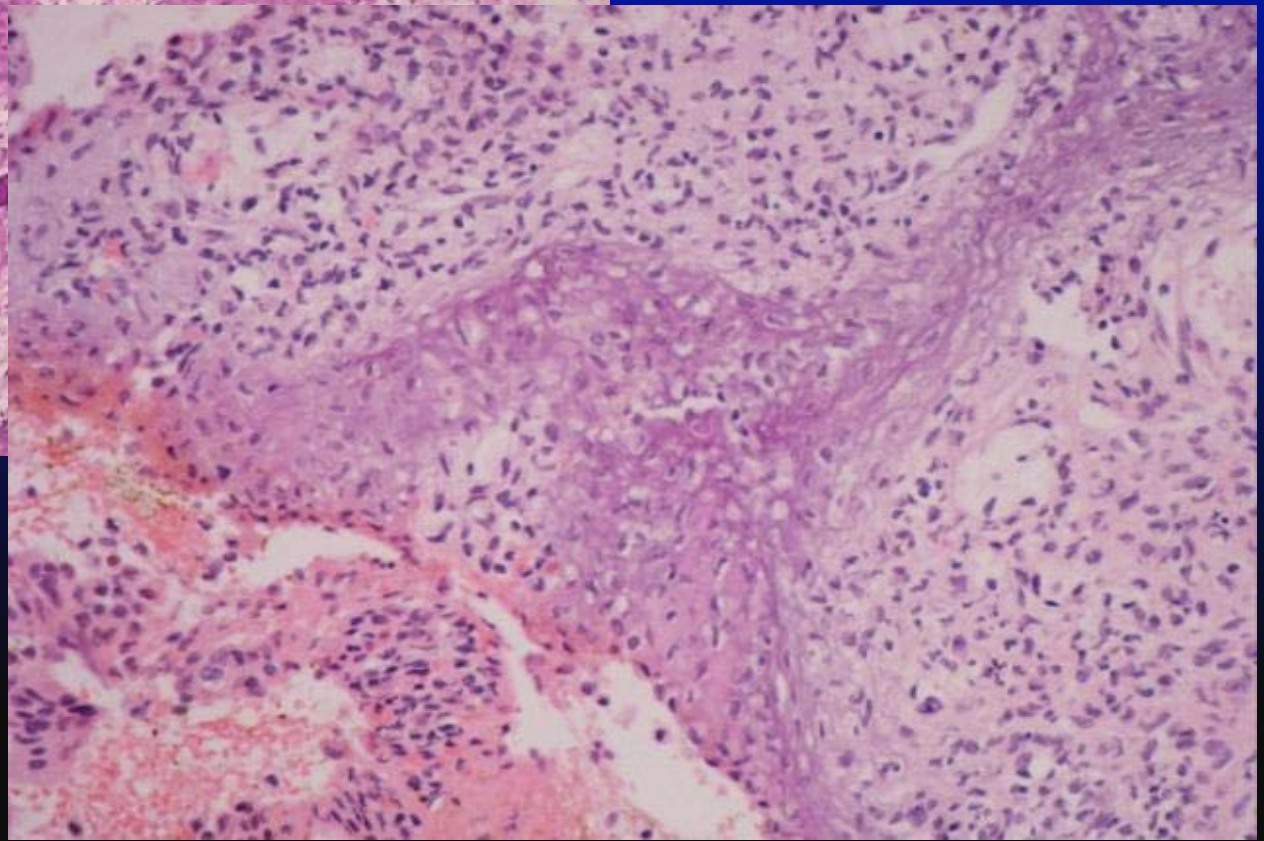
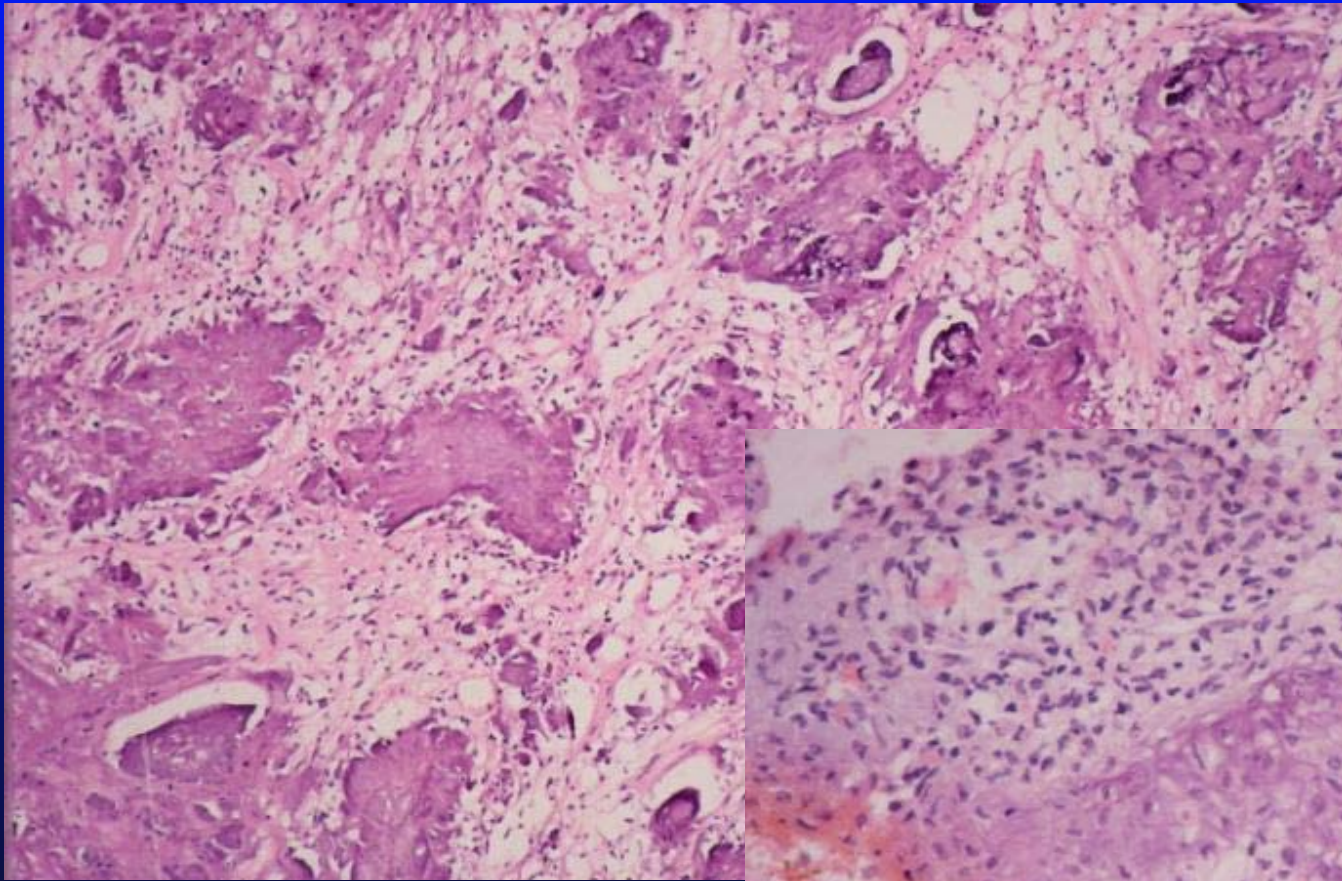


1 14 91
STANDING



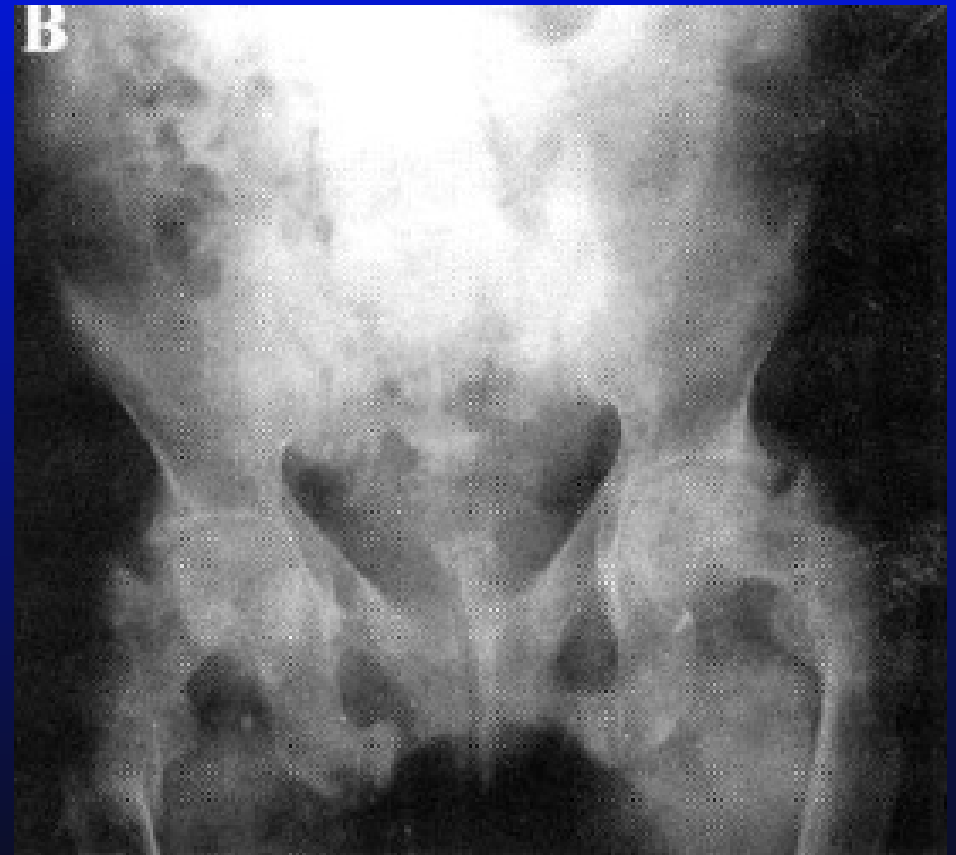
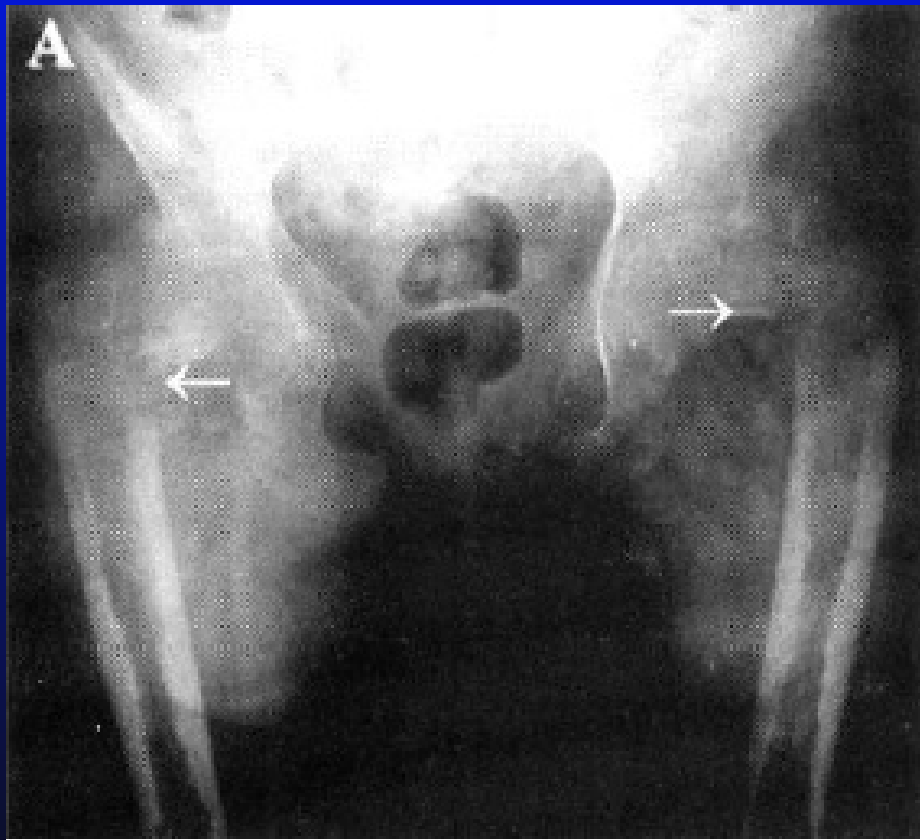






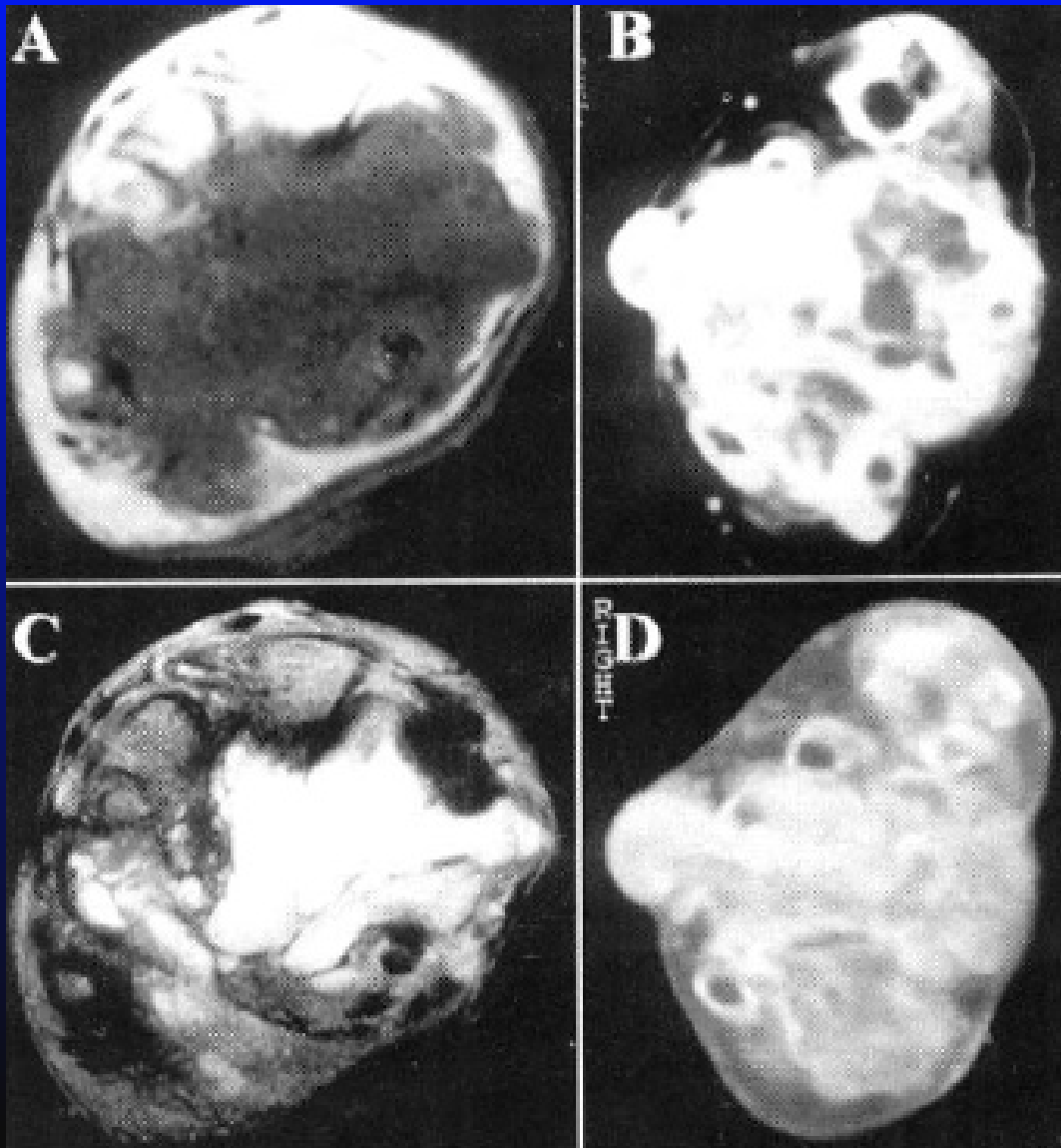
Case #1

- 56-year-old woman
- Diffuse, increasing multiple bone pain
- Generalized fatigue & difficulty walking for 3 years
- Recent history of protruding mass on right foot sole.

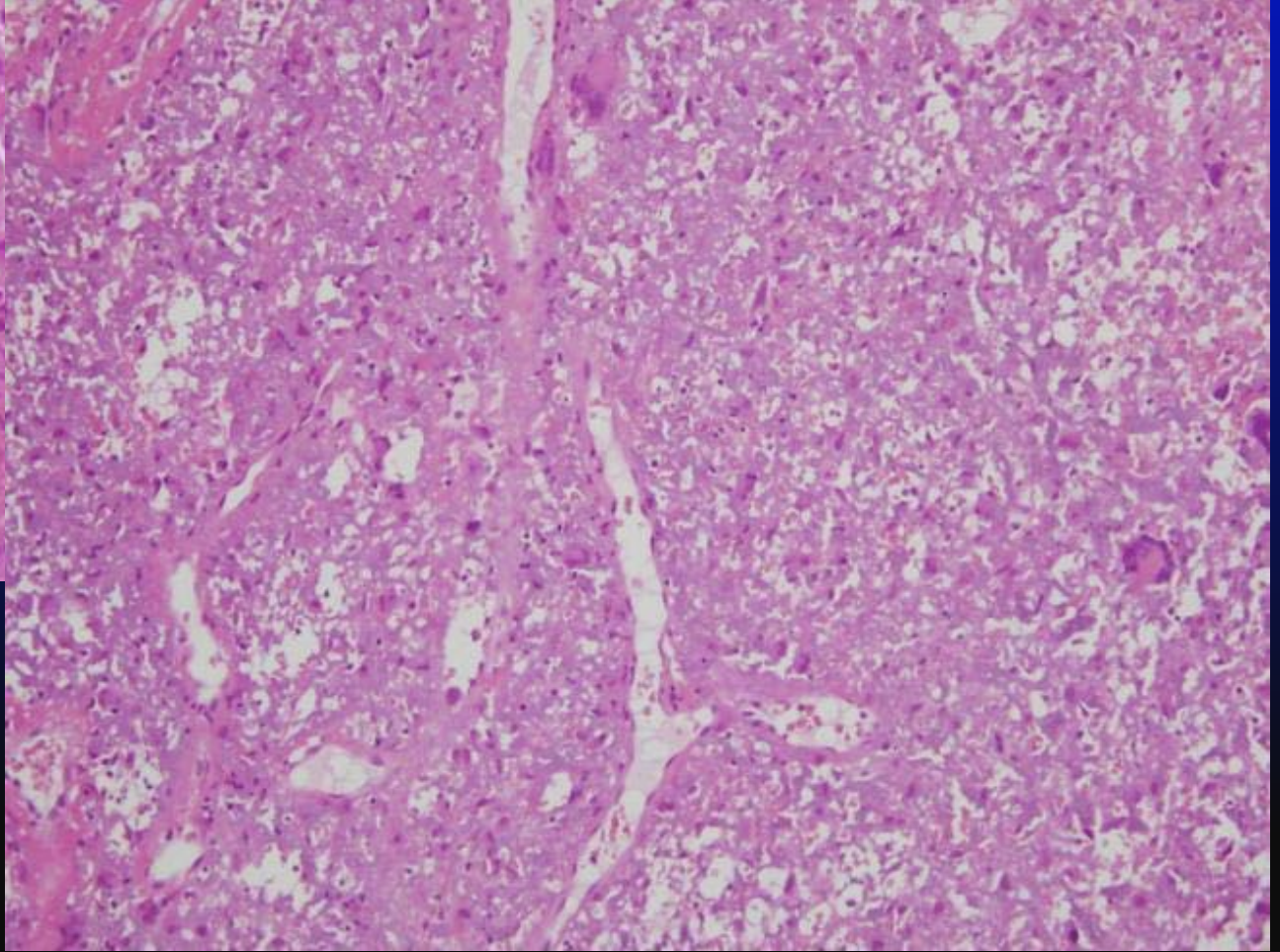
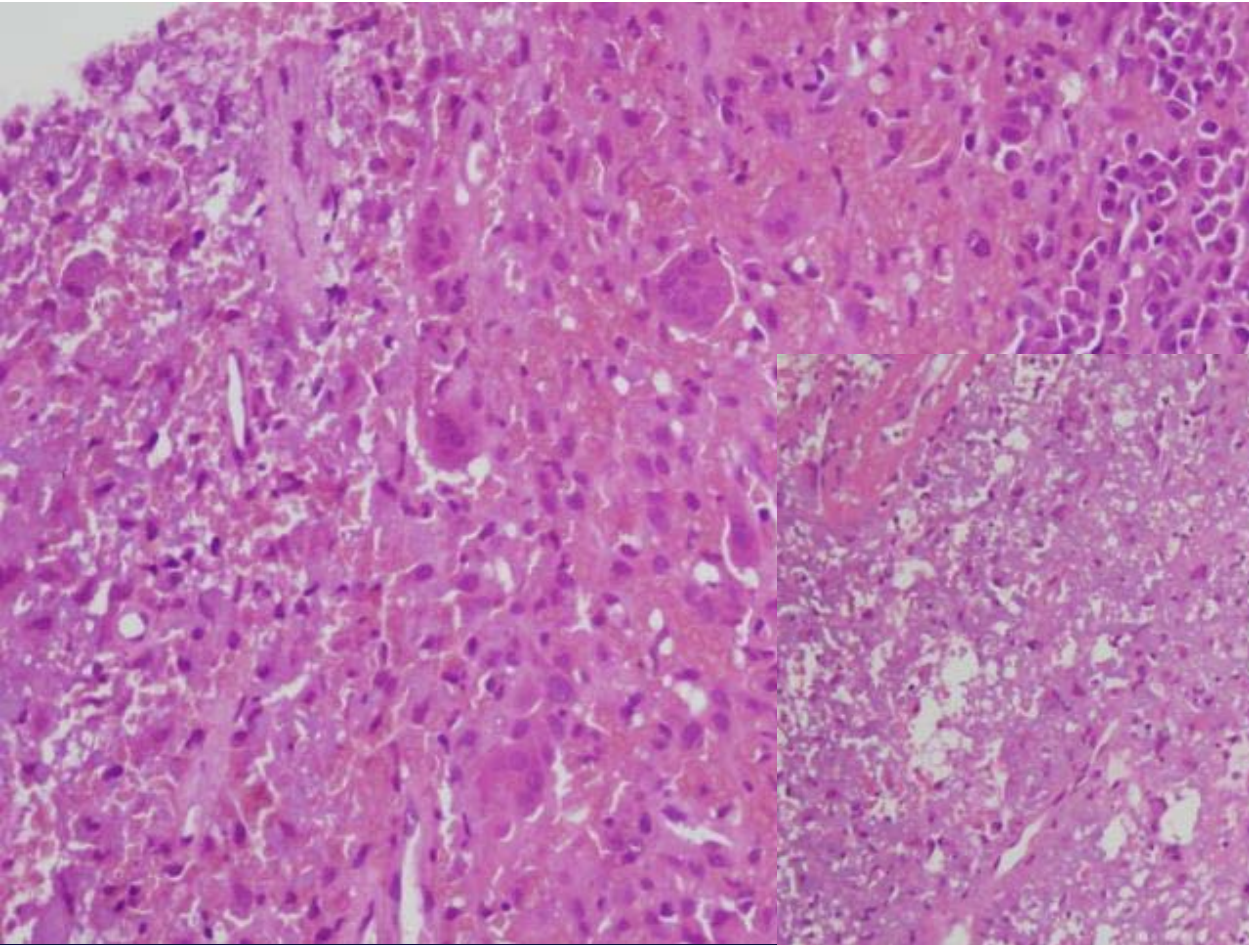


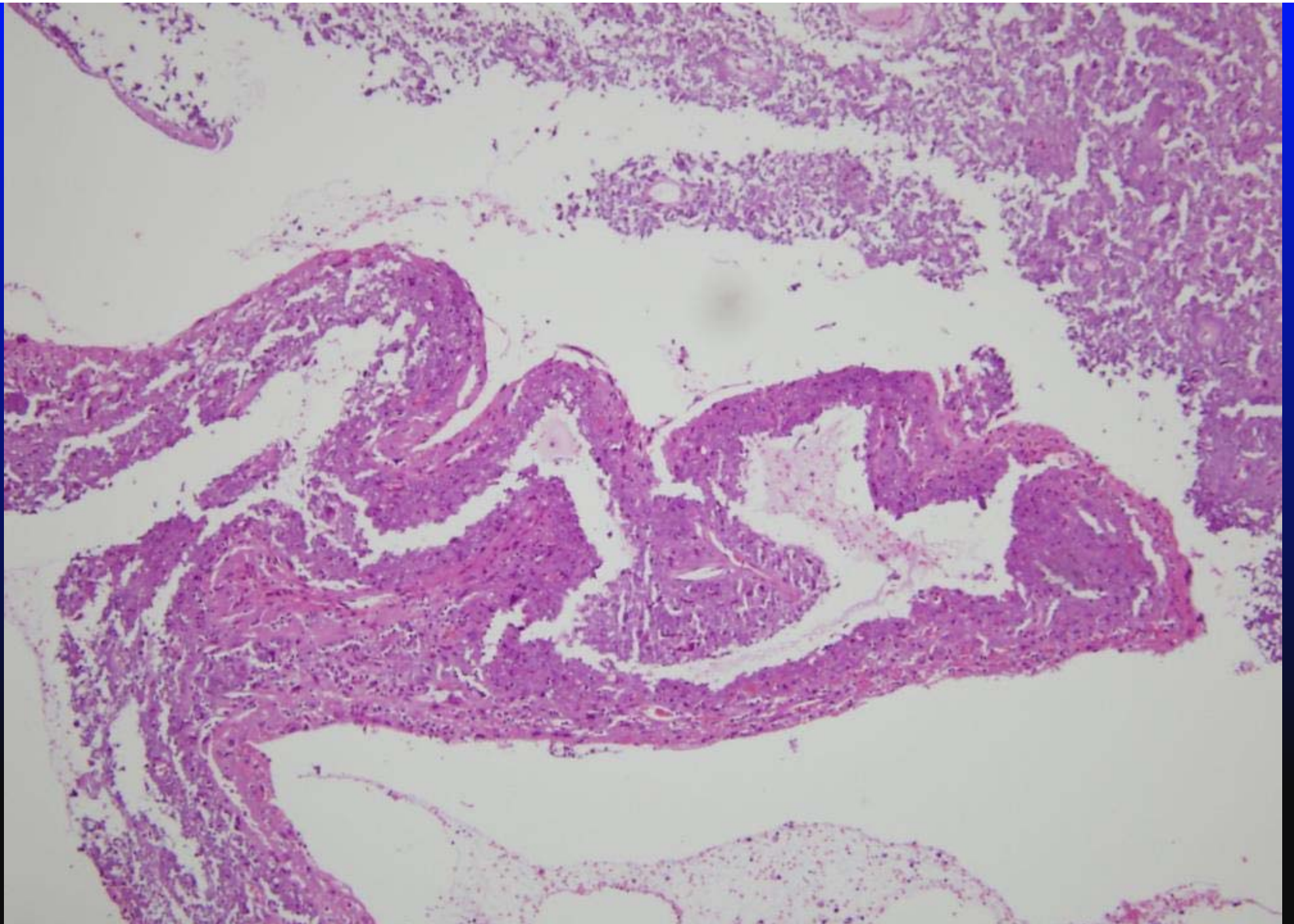
6 months follow-up

Courtesy Oh, KW et al. 1999

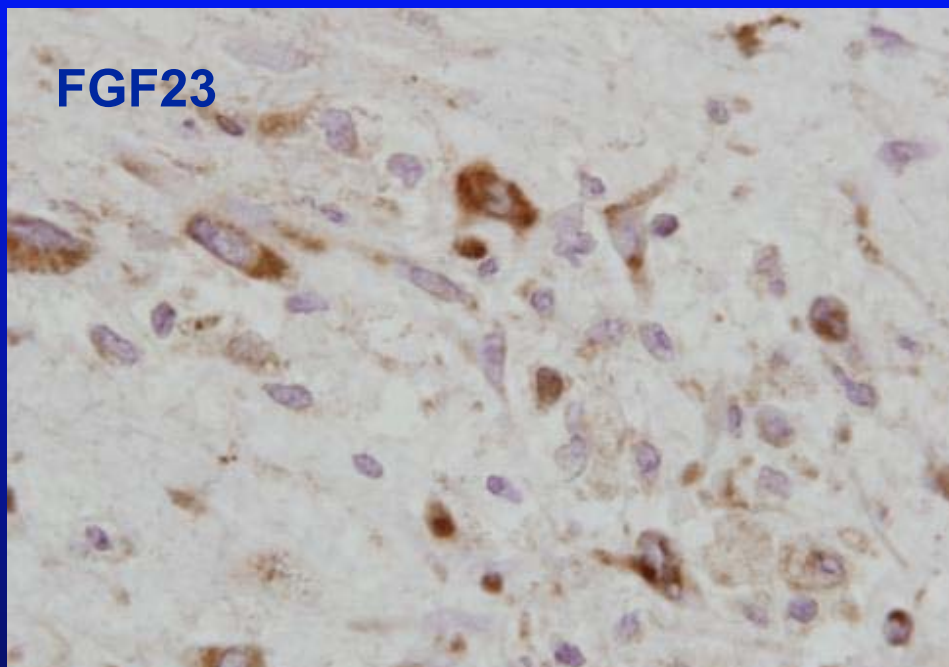


Courtesy Oh, KW et al. 1999

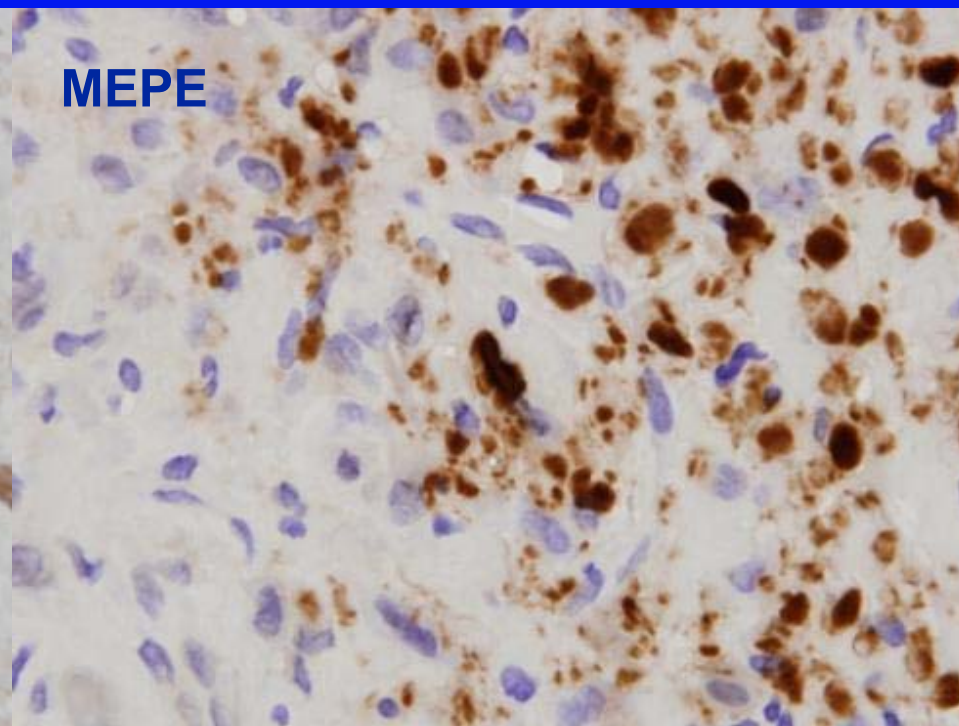




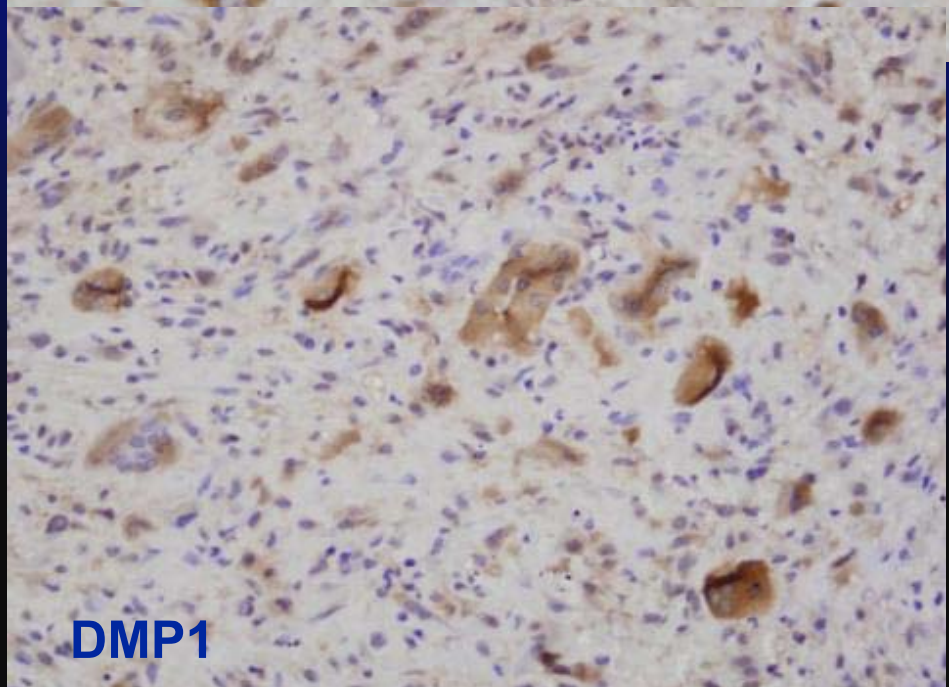
FGF23

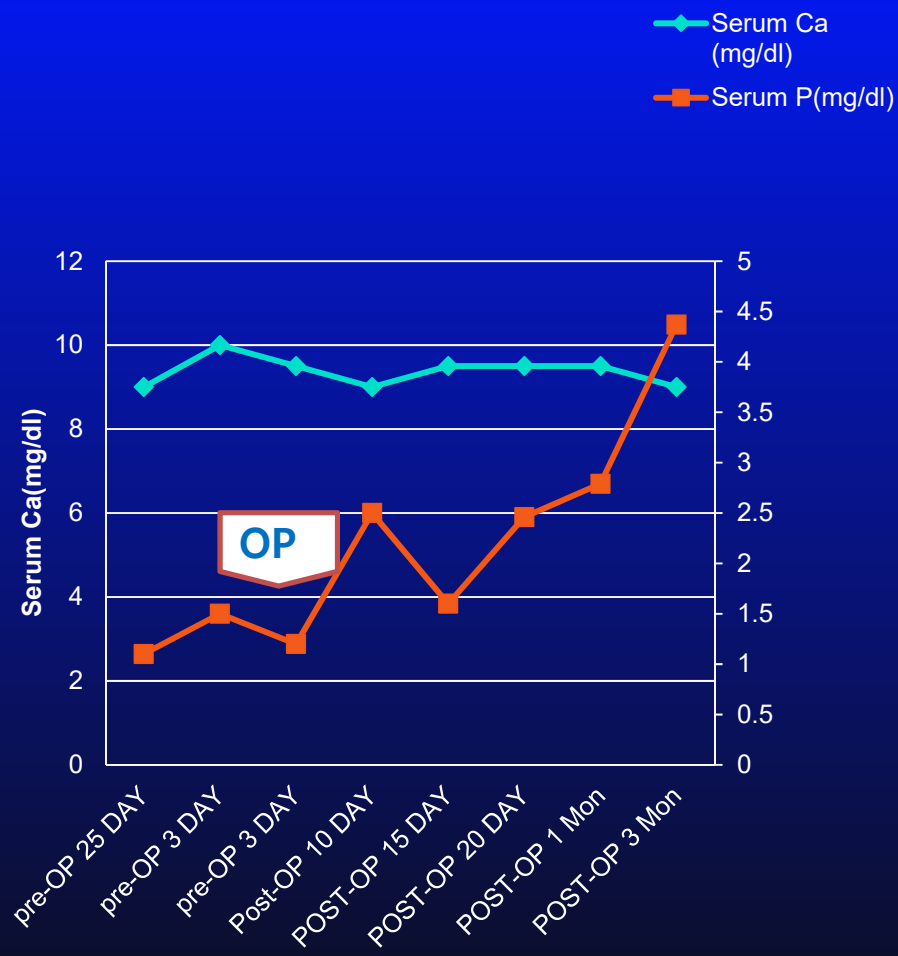


MEPE

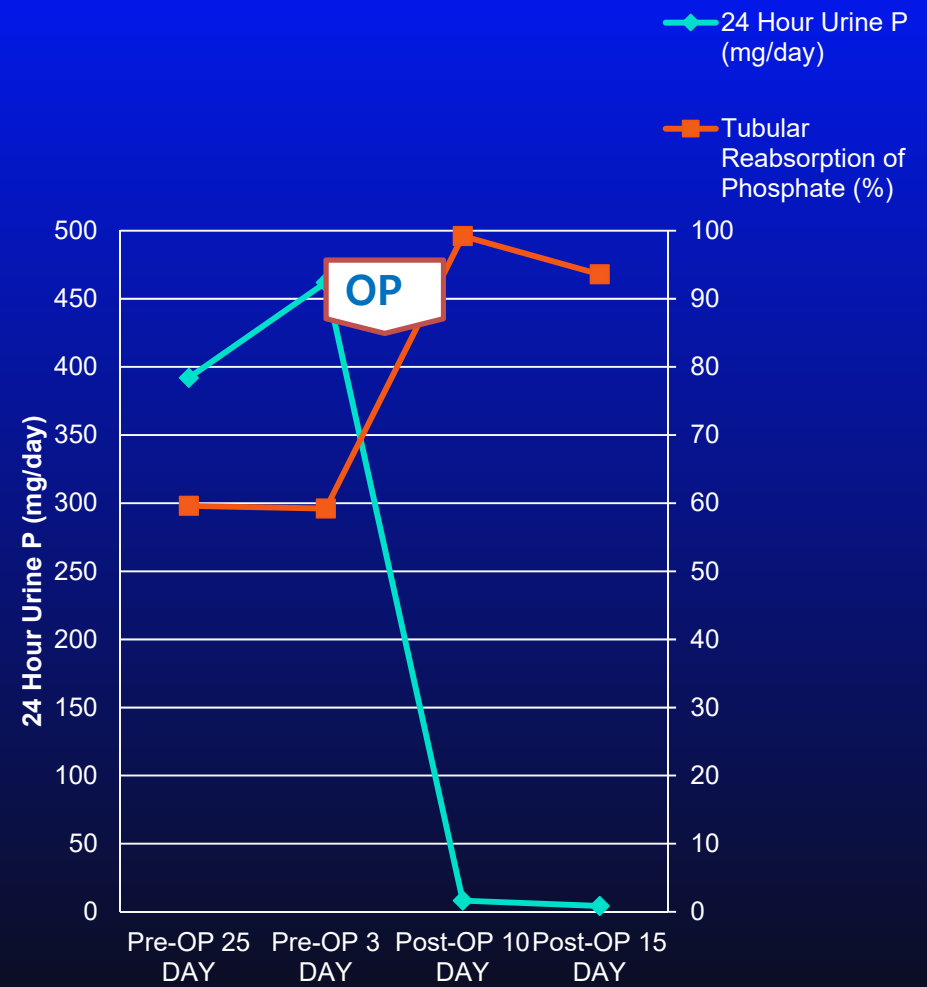


DMP1





The changes of serum calcium and phosphate levels

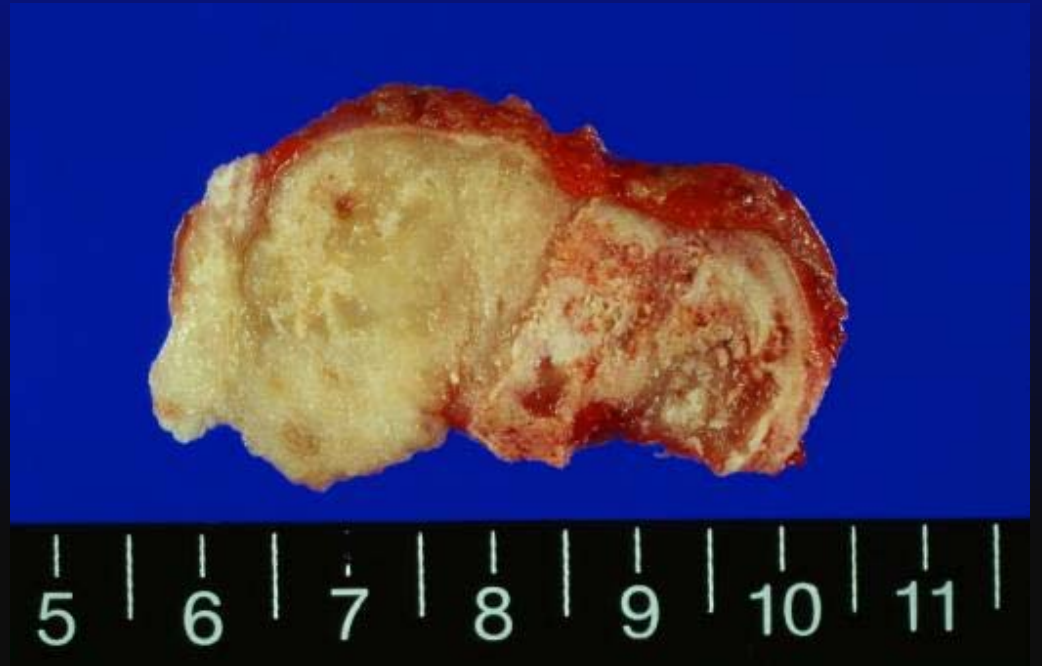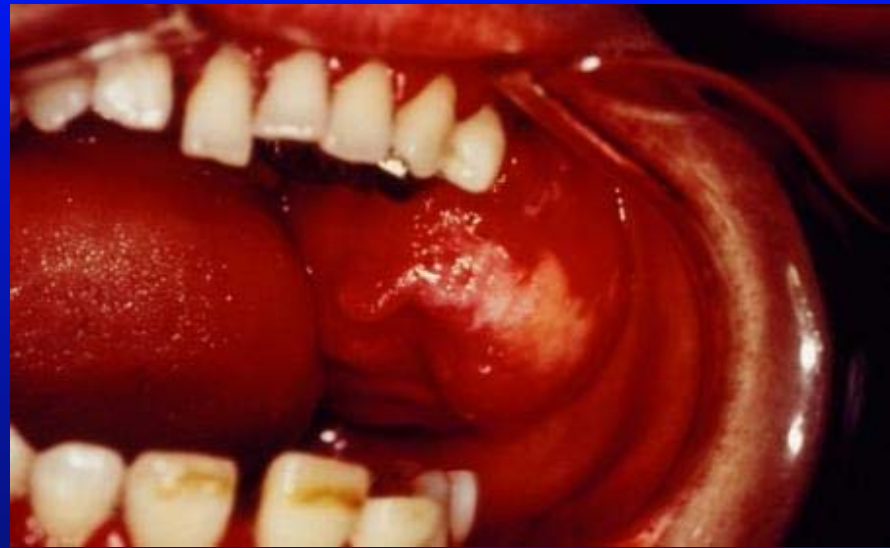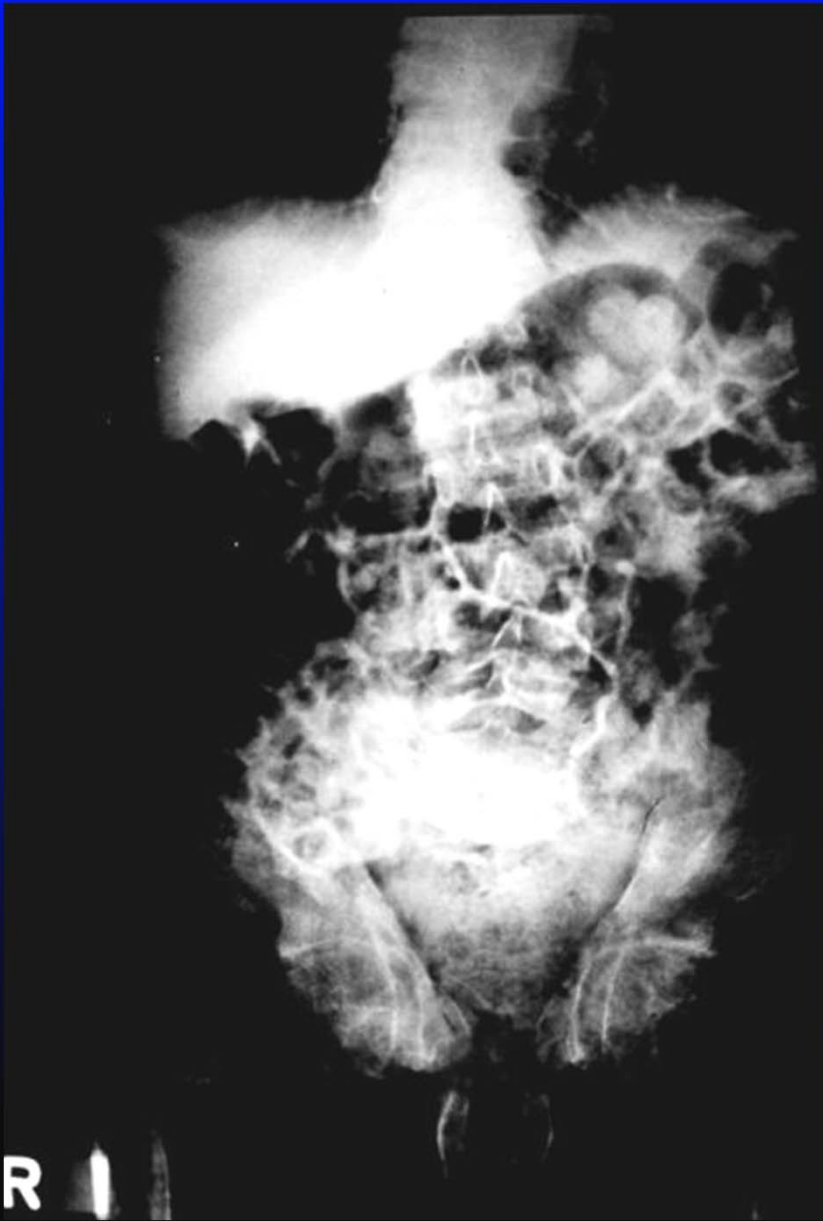


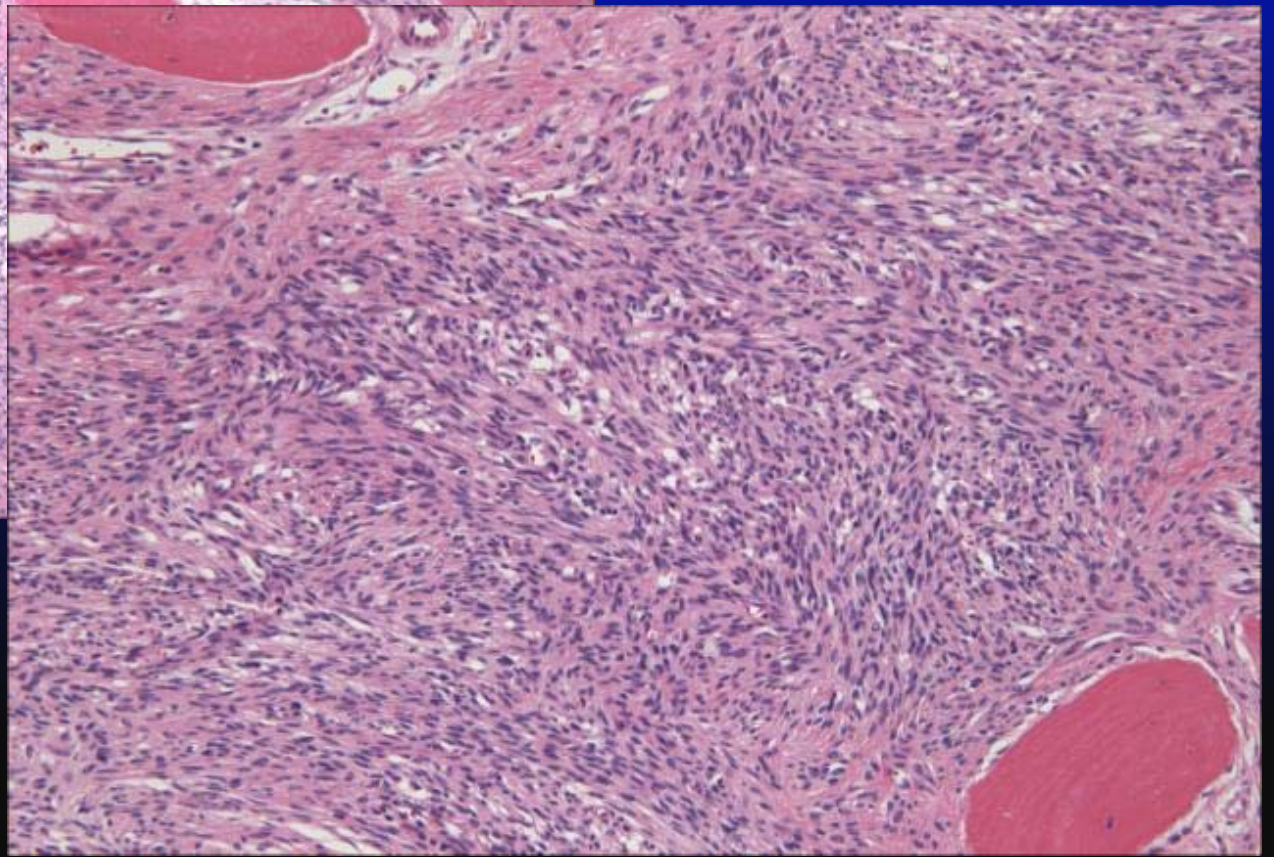
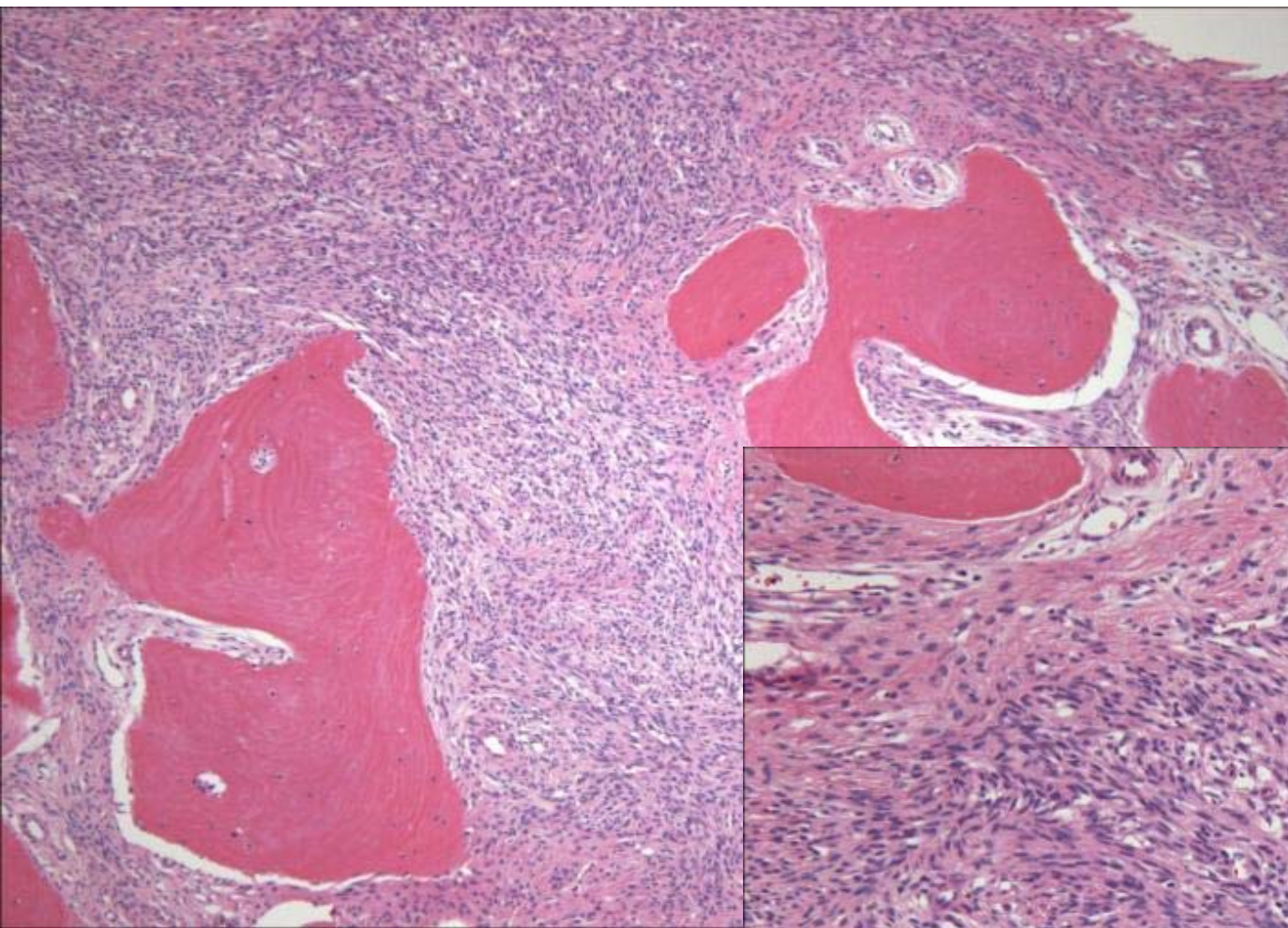
The change of urine phosphate excretion and TRP.

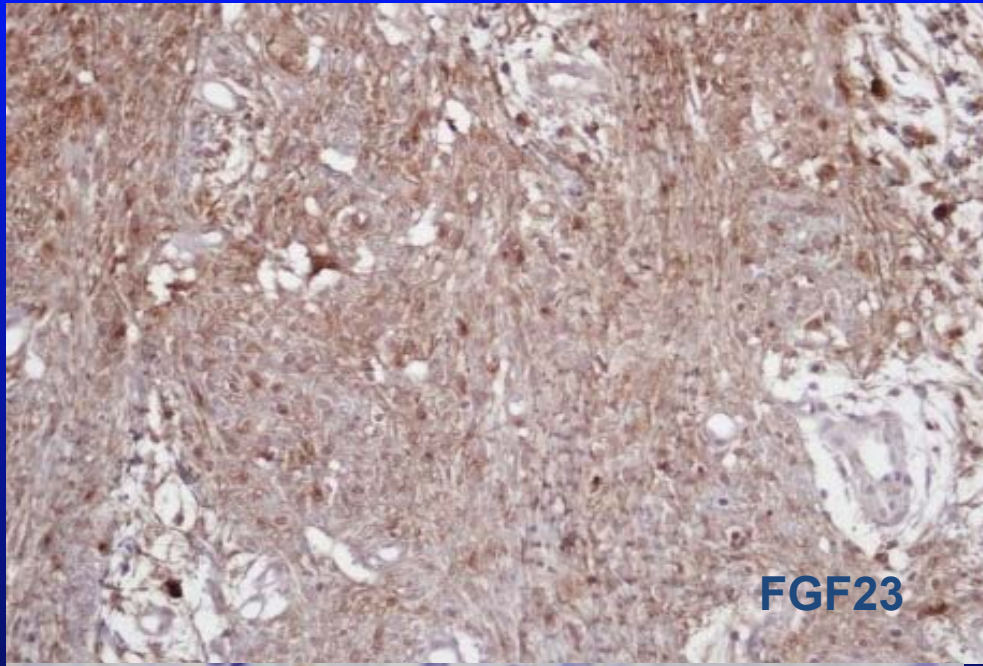
Courtesy Oh, KW et al. 1999

Case #2

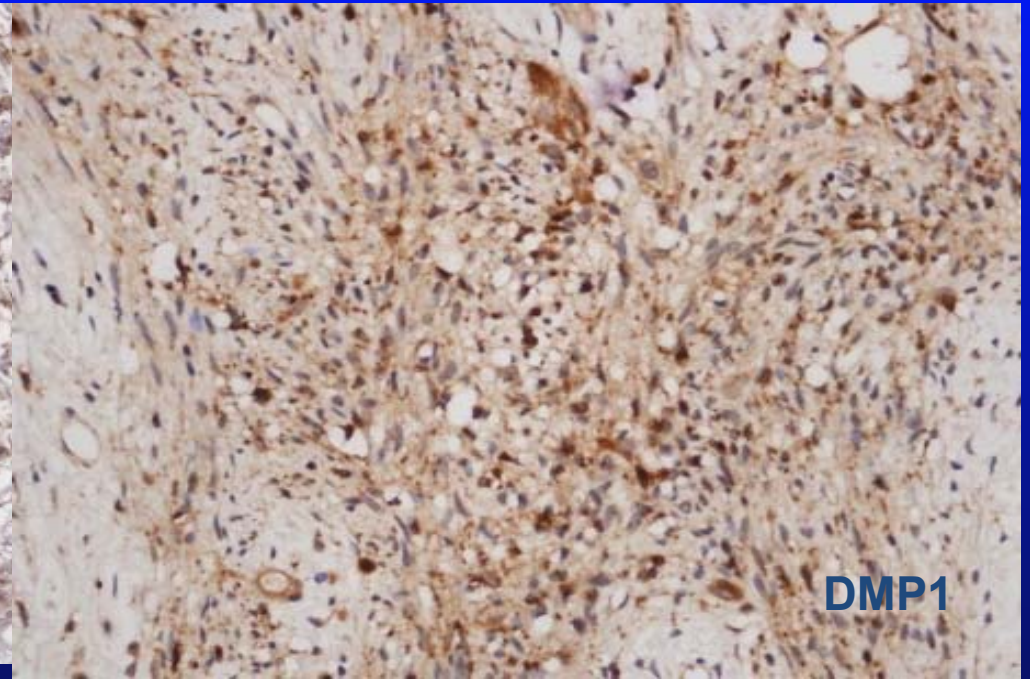
- F/31yo
- Known osteomalacia for 10 years
- Lesion on her oral cavity mass
- Tetracycline double labeling and bone biopsy



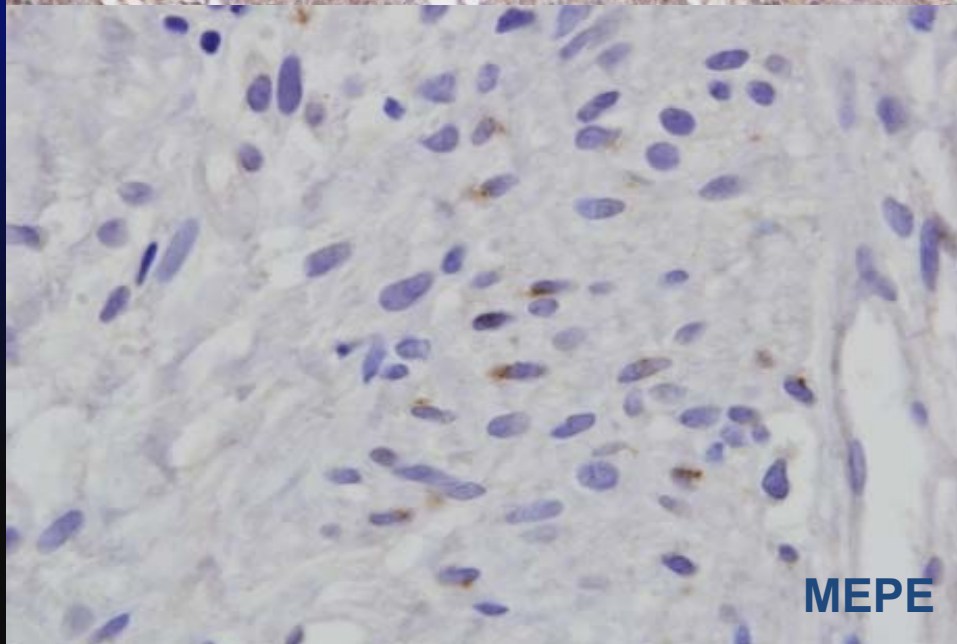




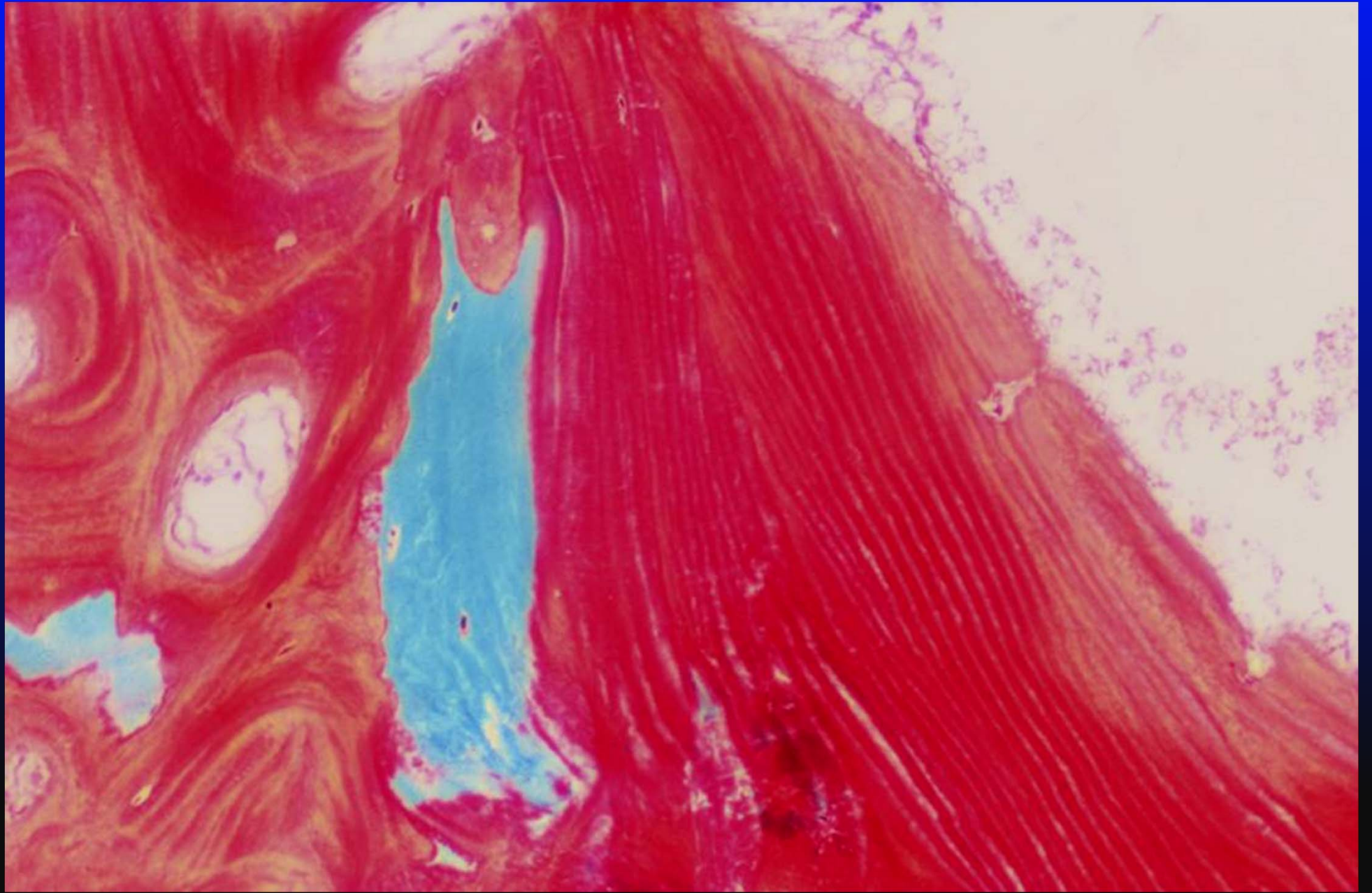
FGF23

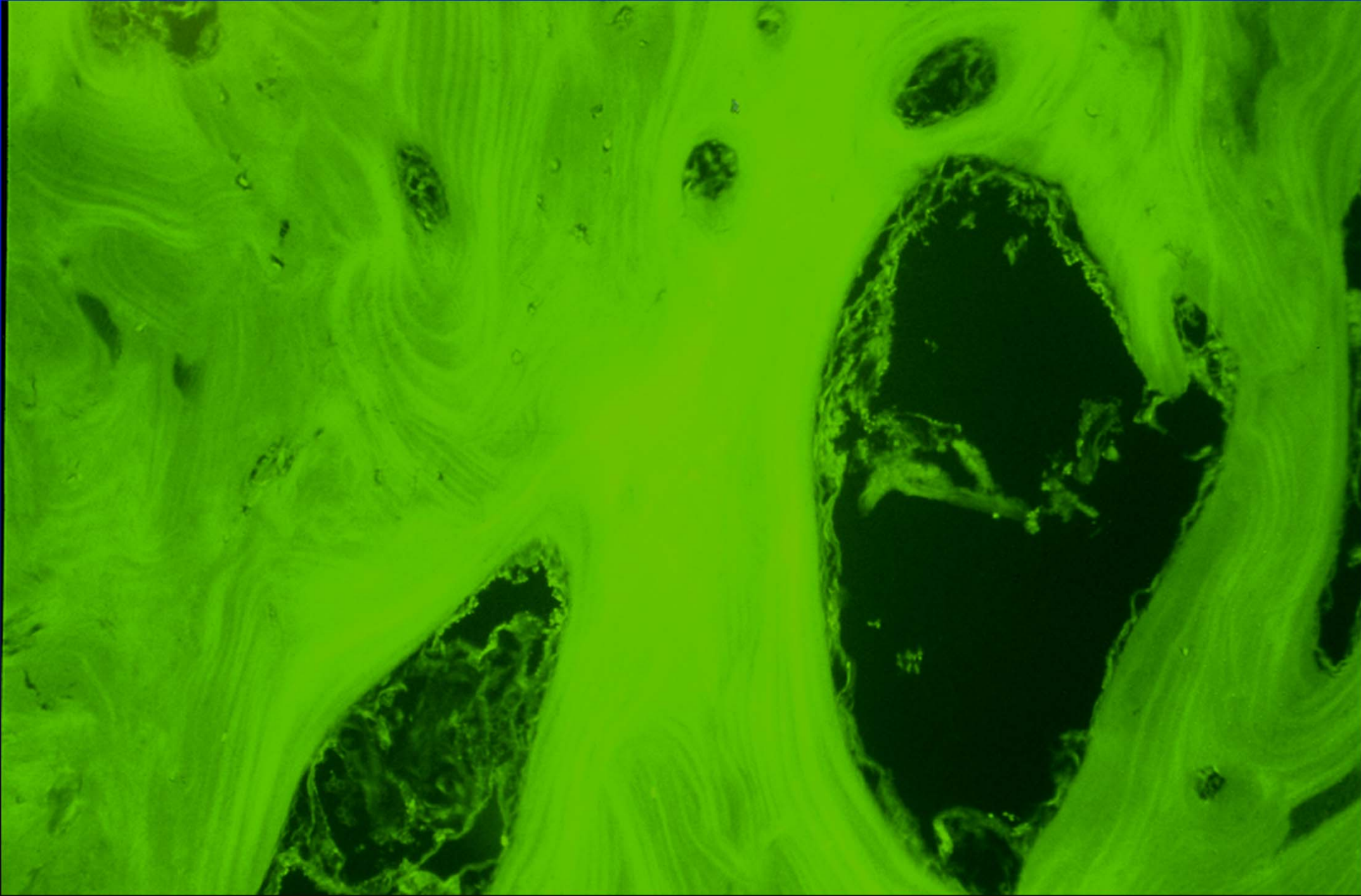


DMP1



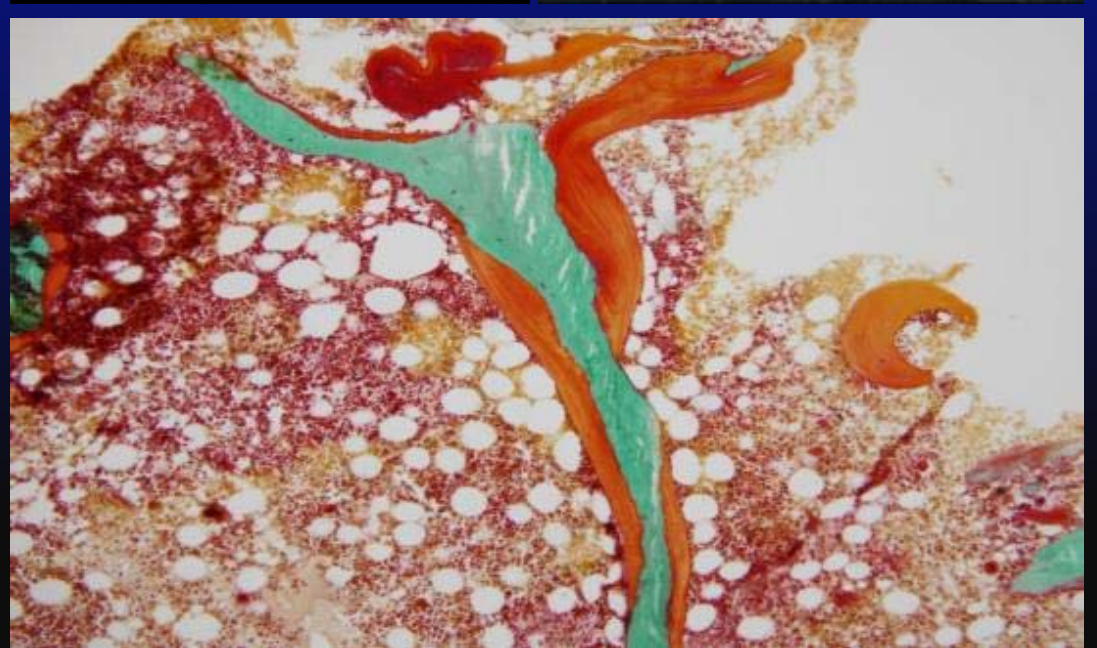
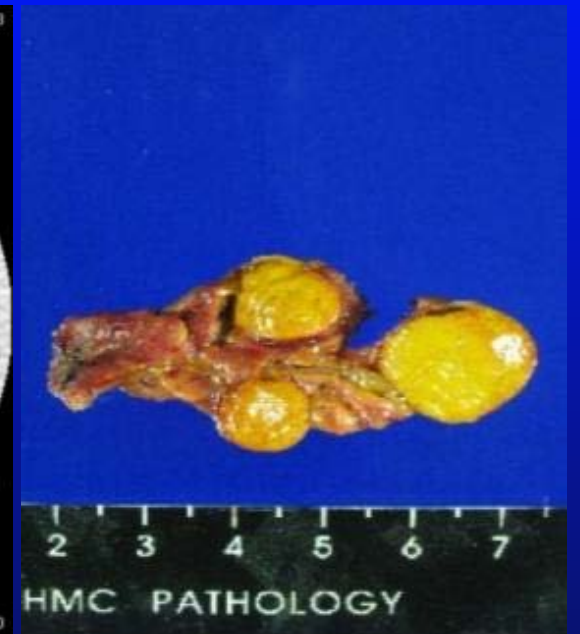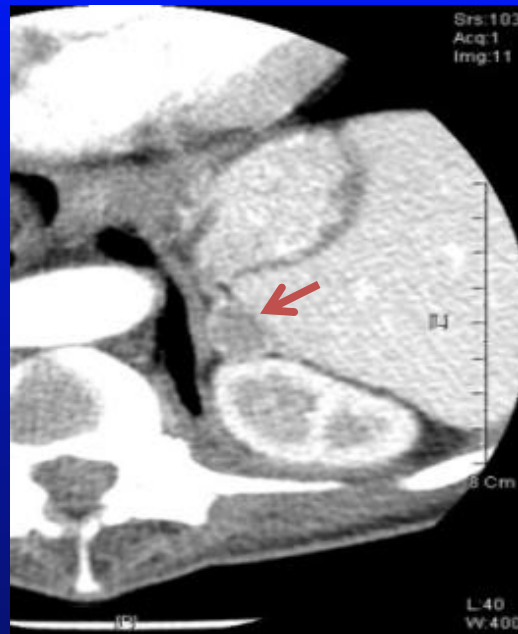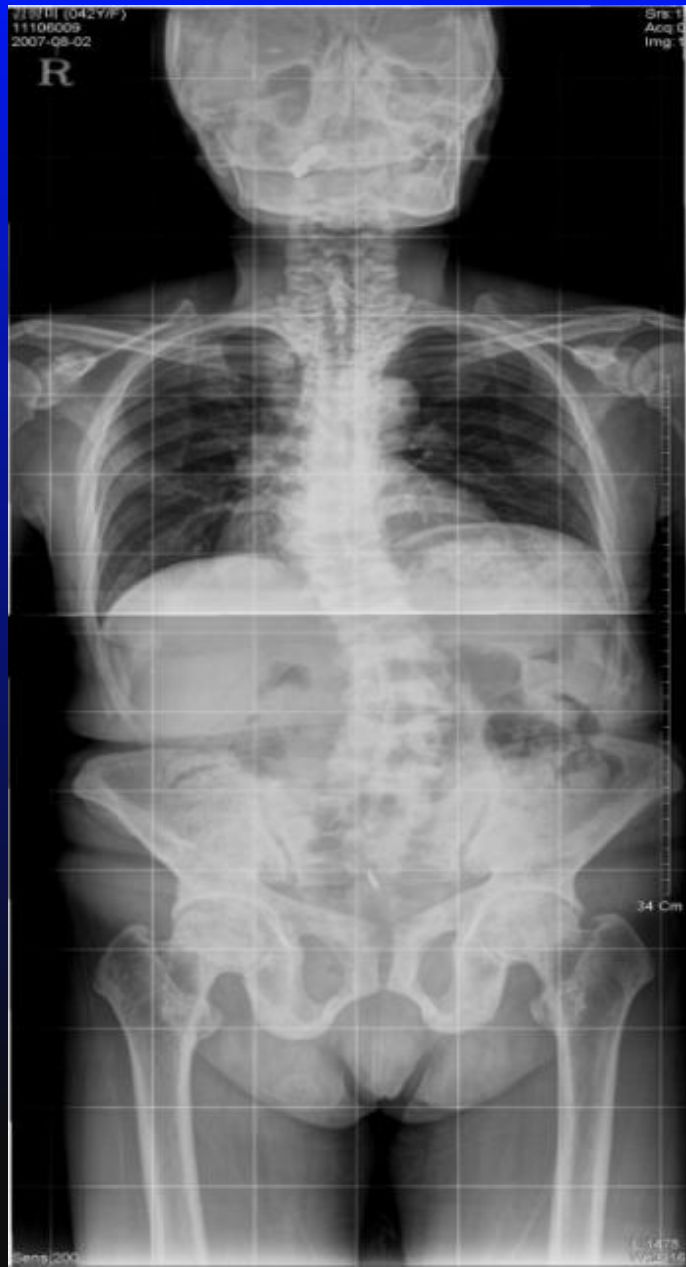
MEPE

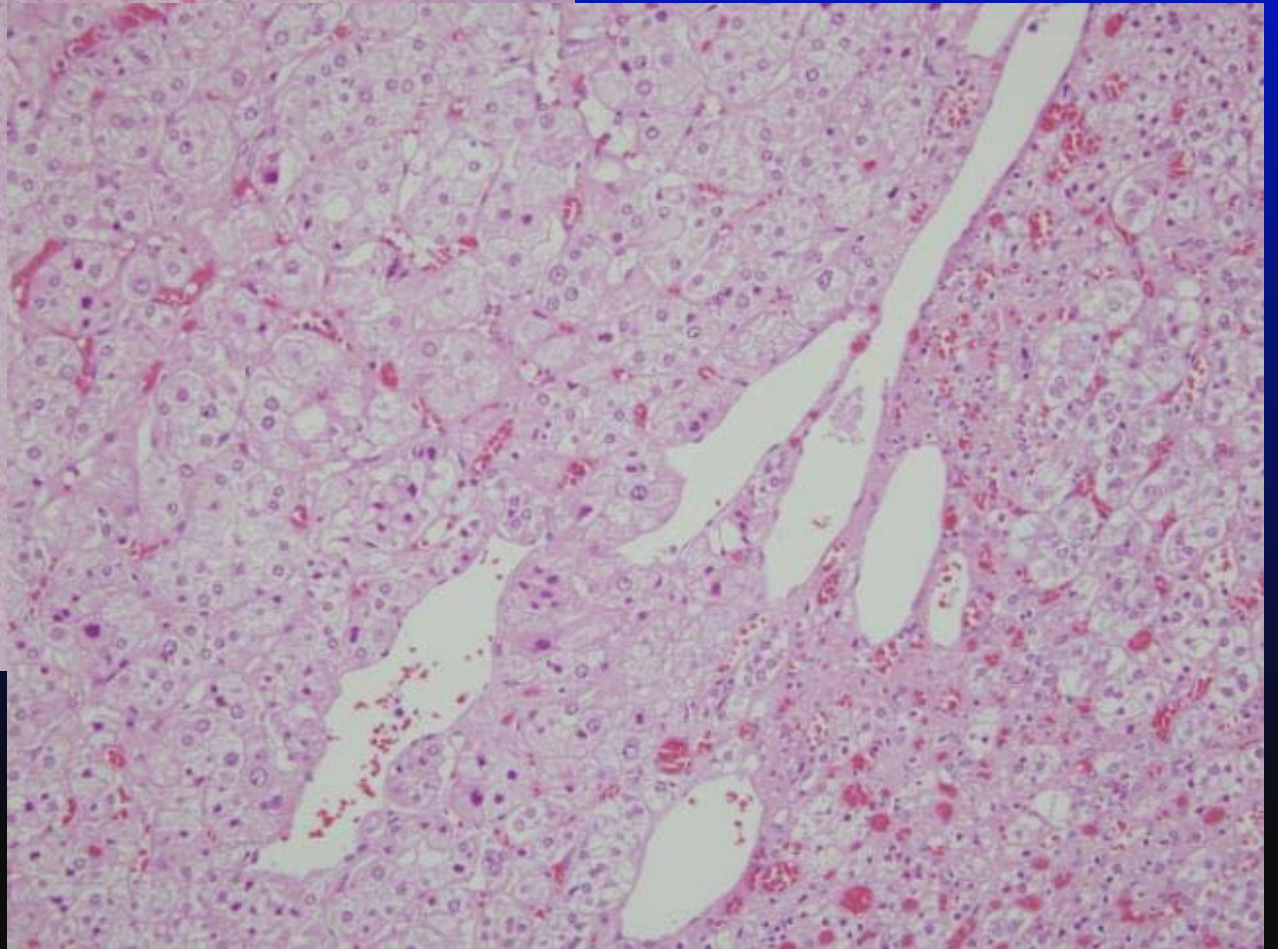
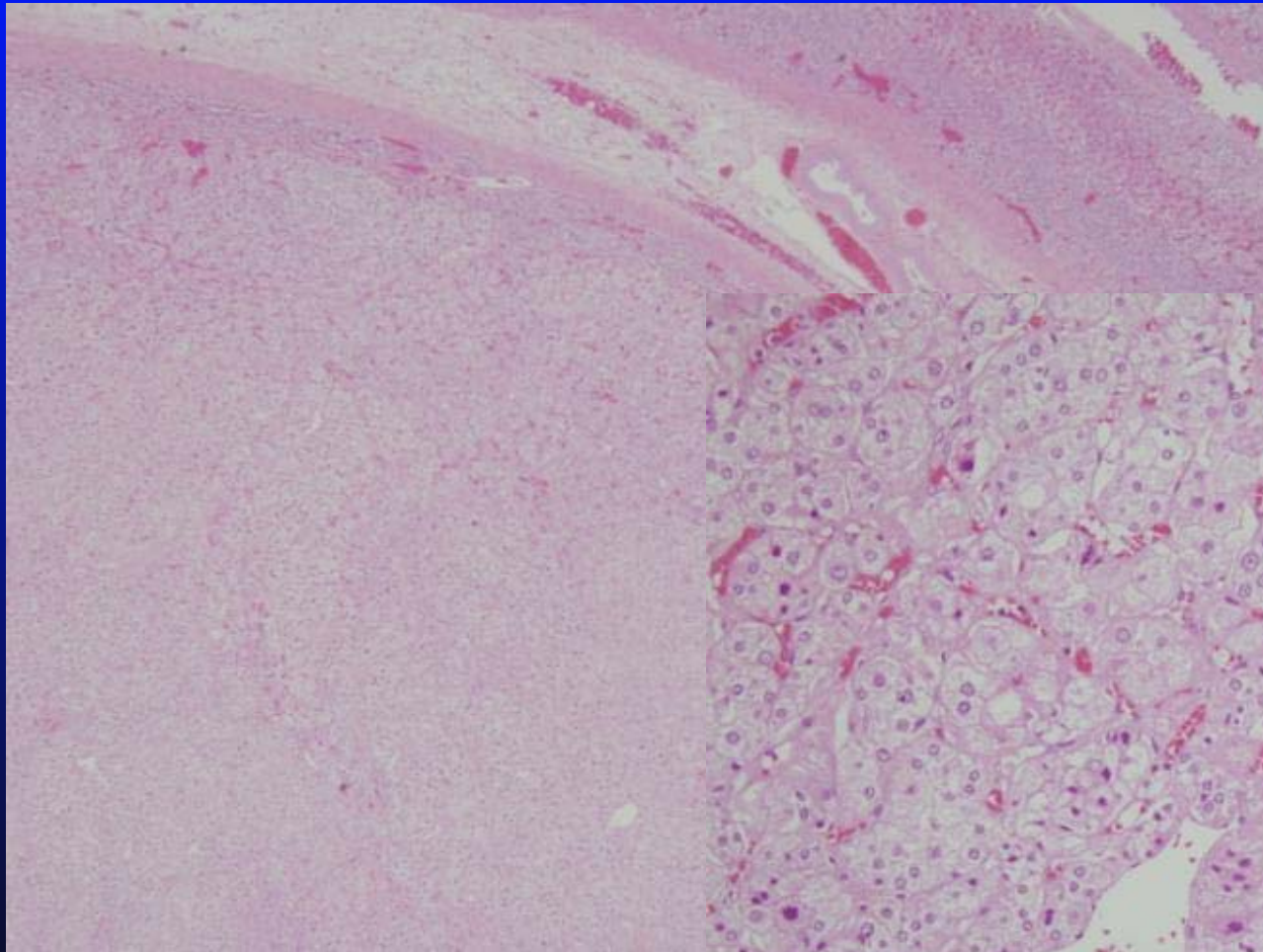


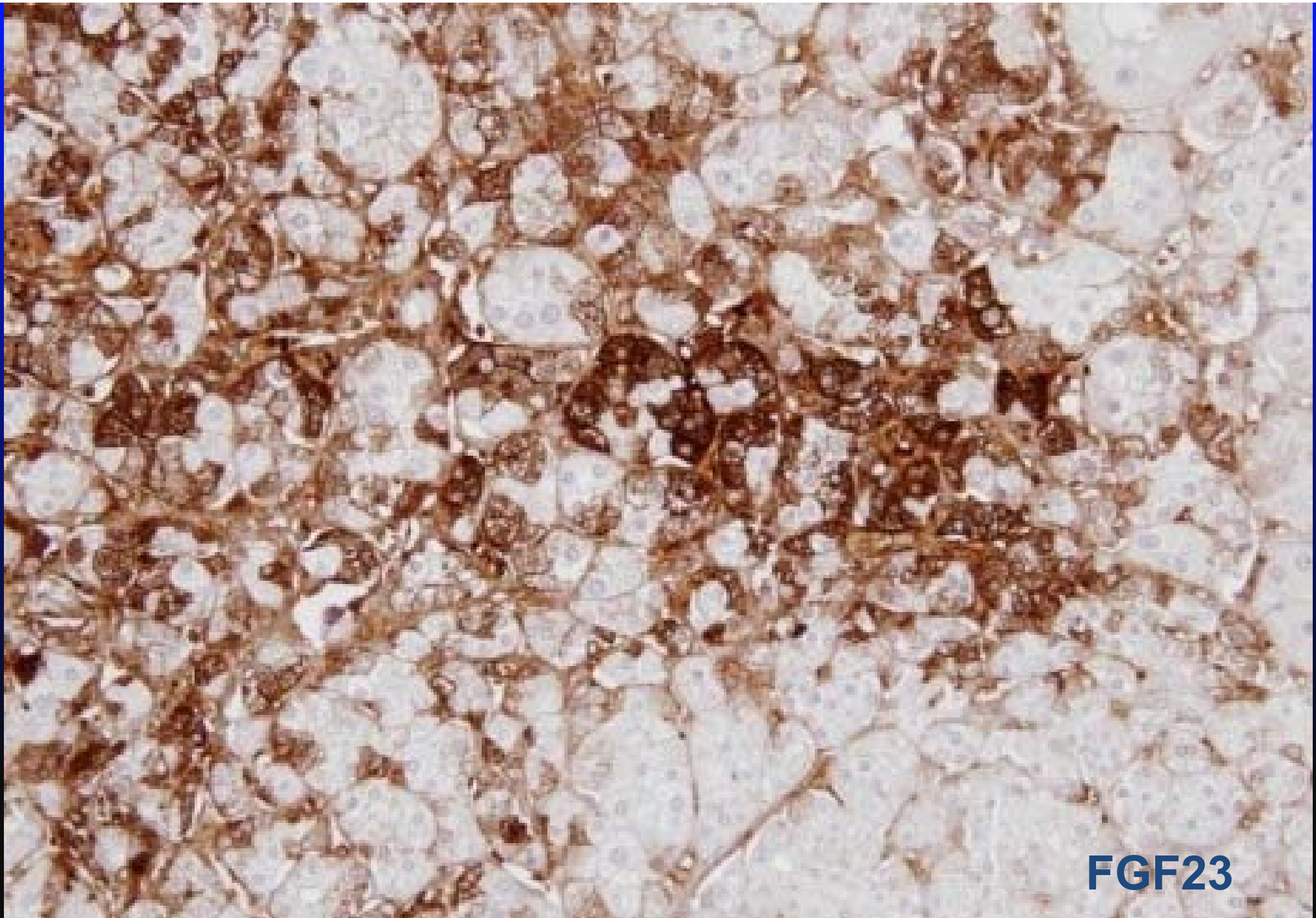


Case #3

- F/42 YO
- C.C.: Generalized bone pain
Loss of Height
Frequent fracture
Since Adolescent
- Past History: Hypertension



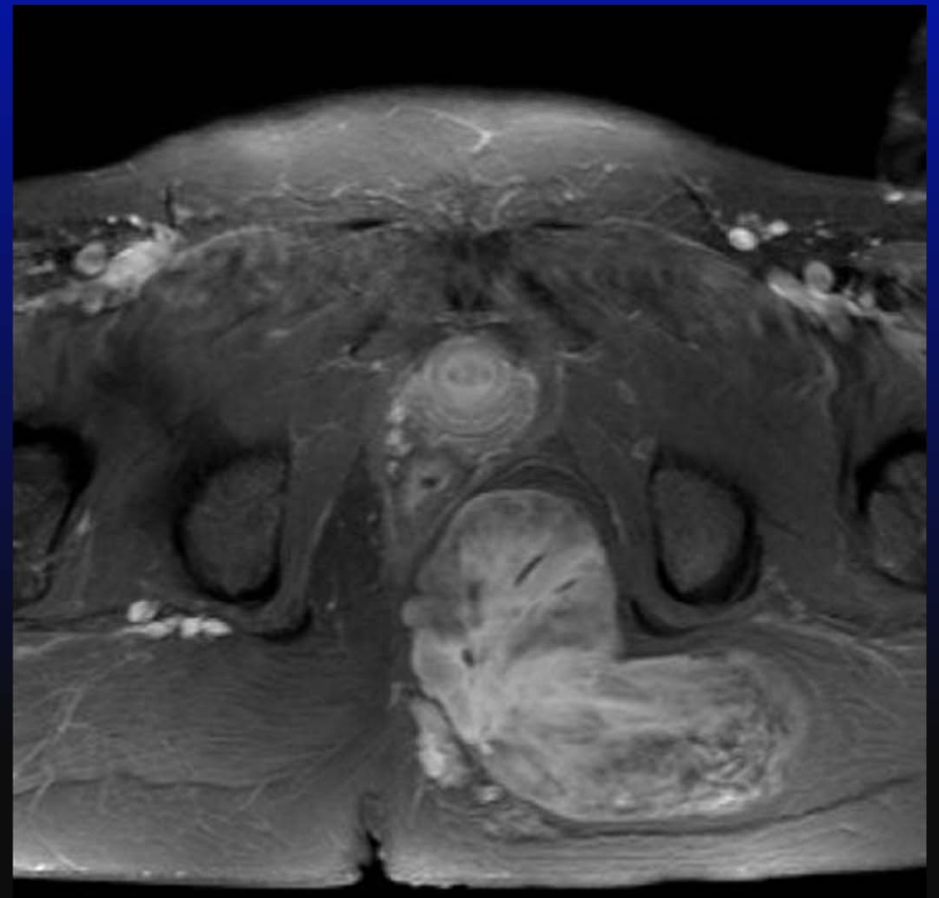
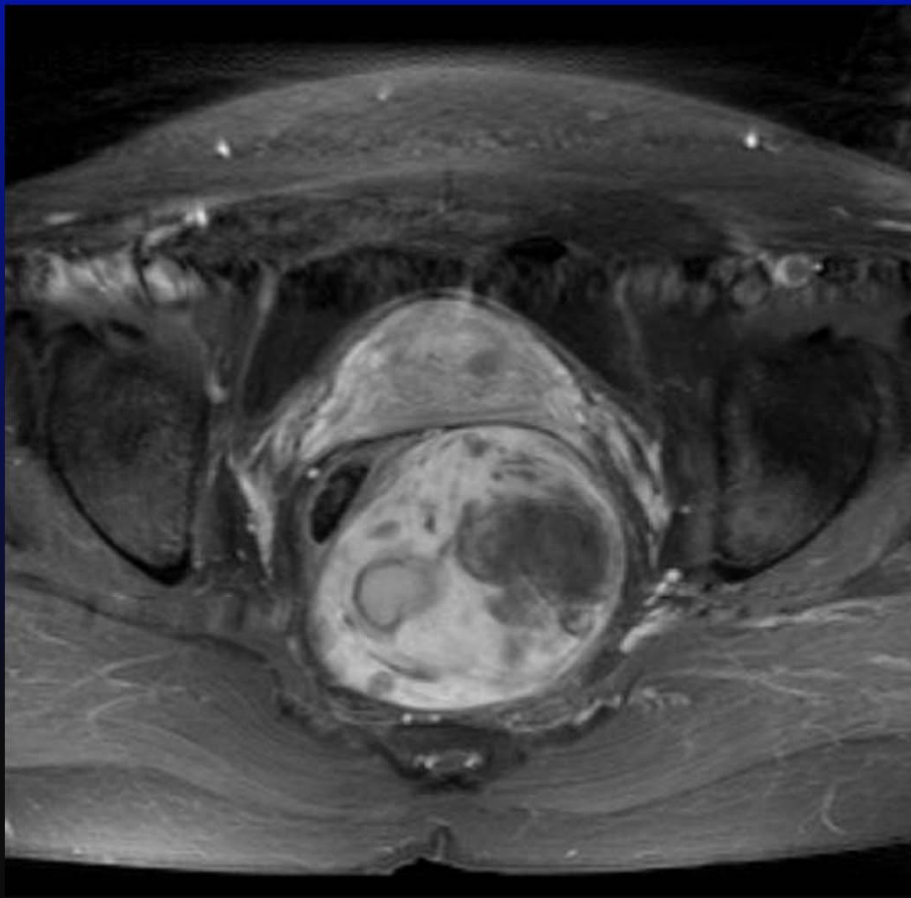


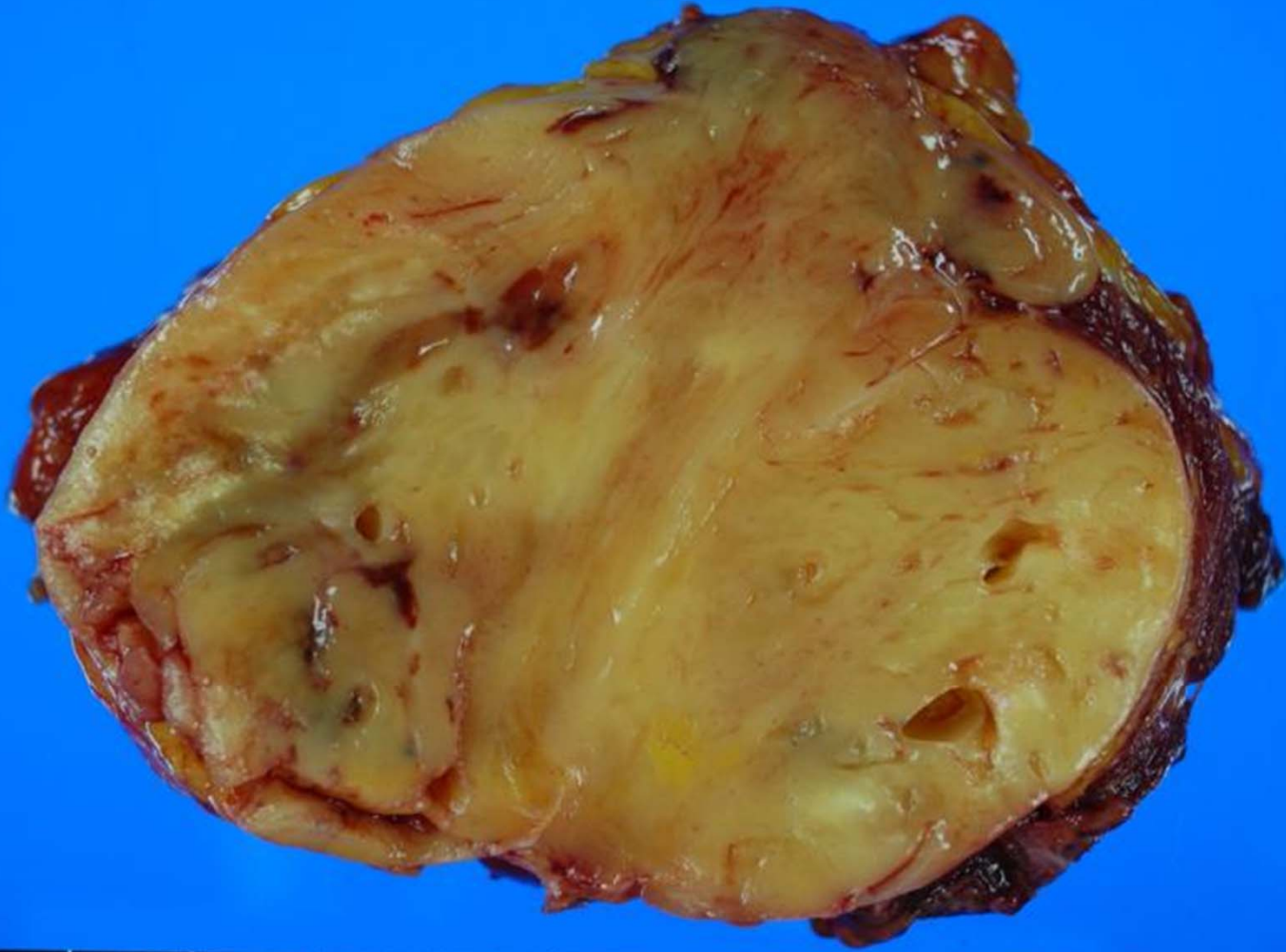


FGF23

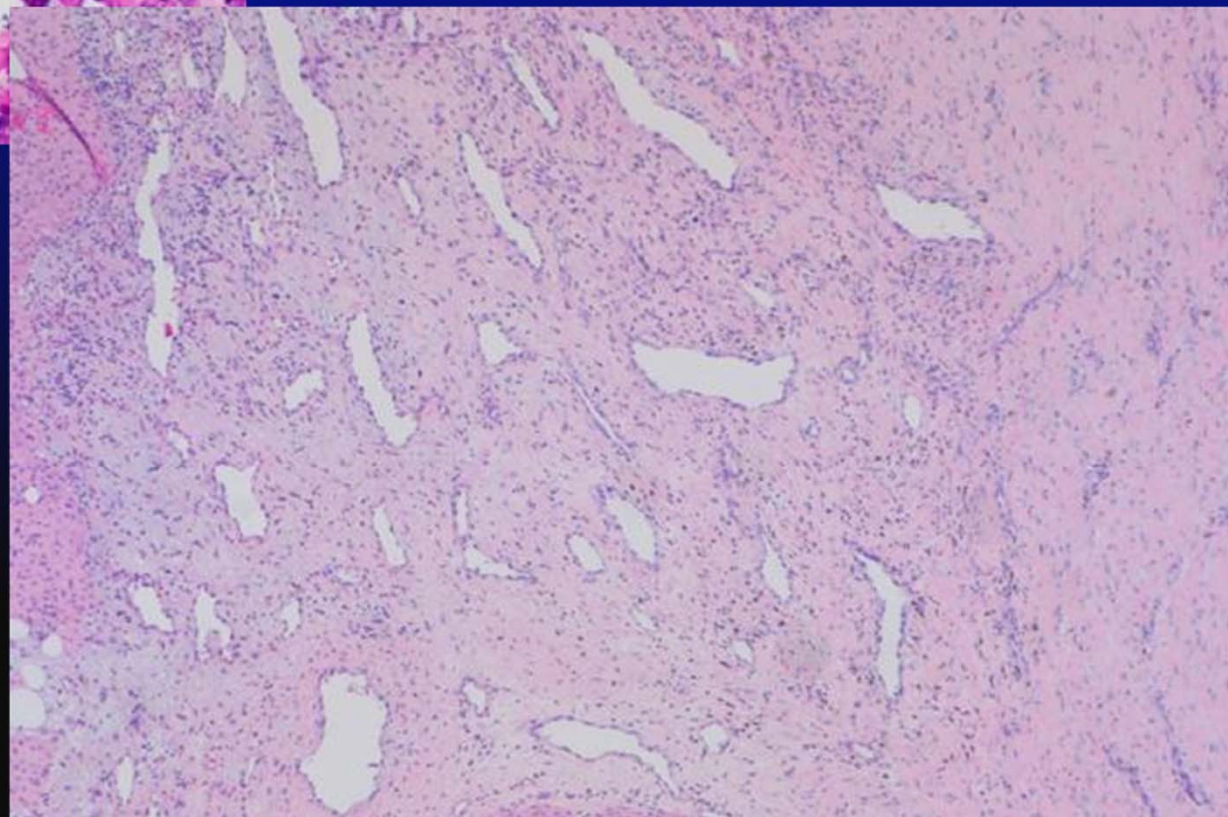
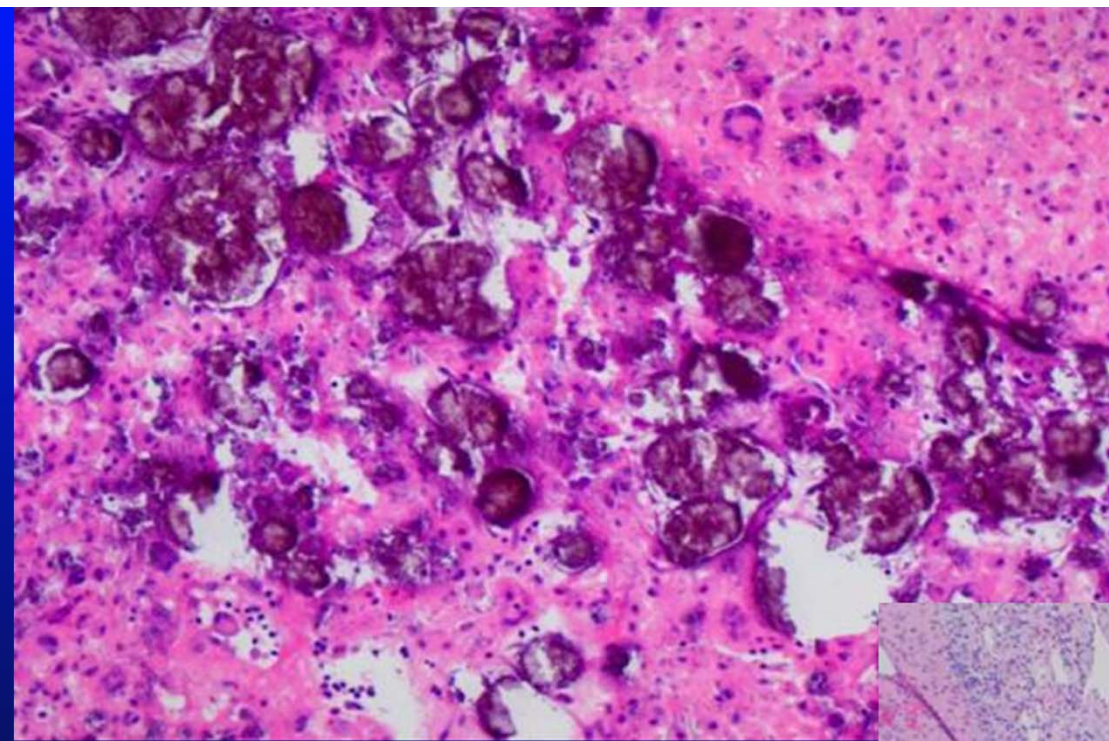
Case # 4

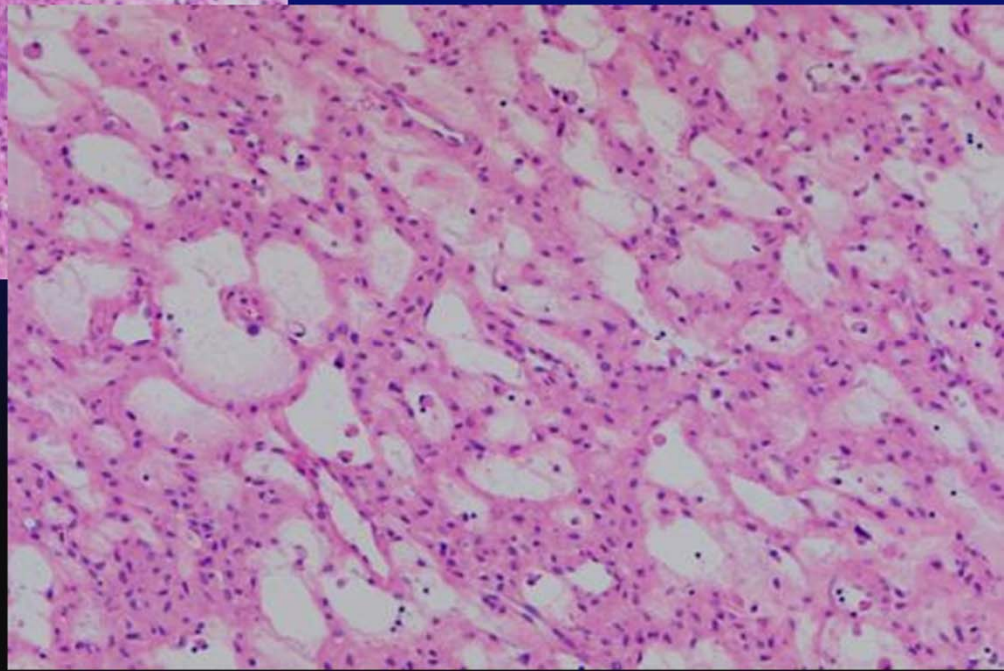
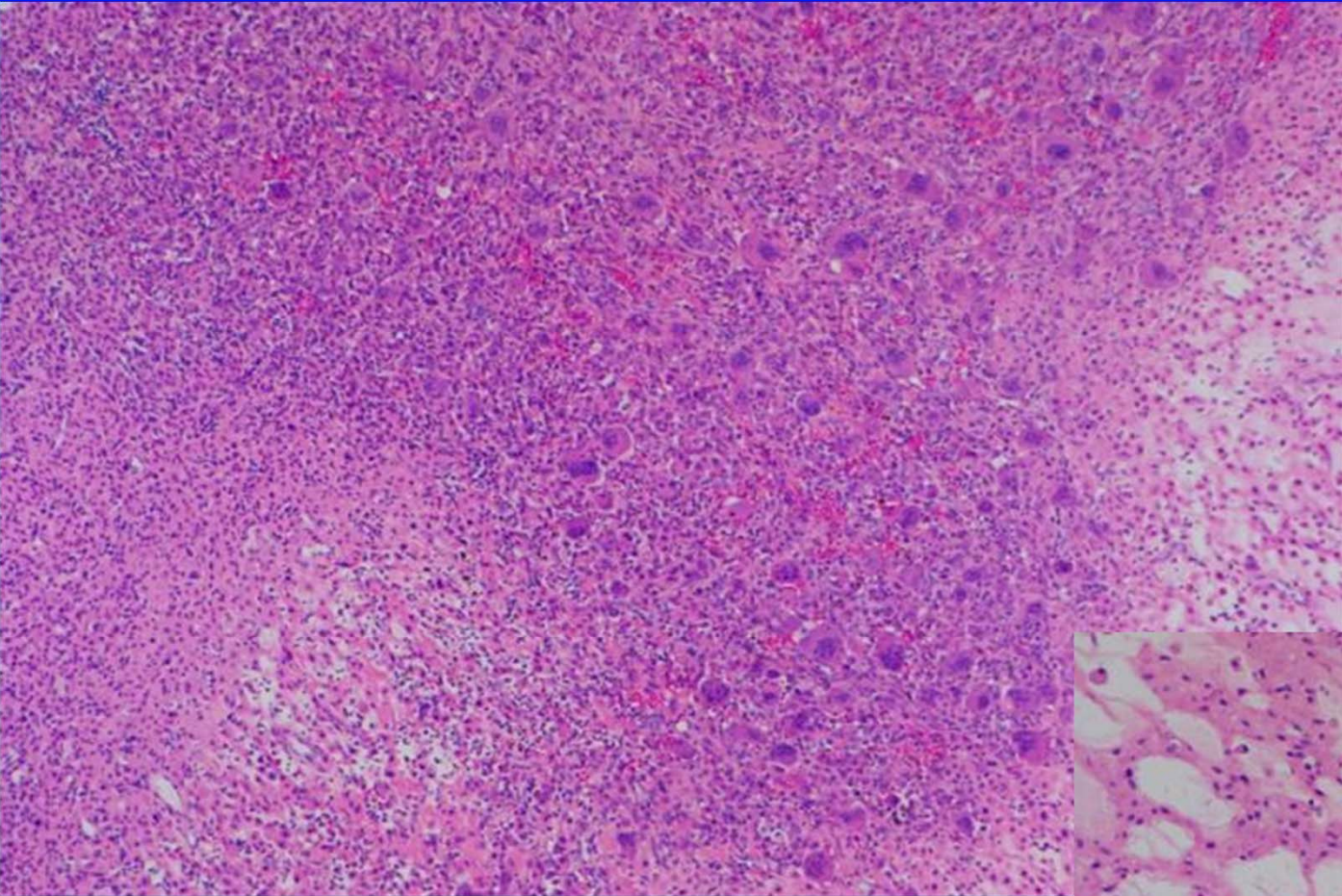
- F/45 YO

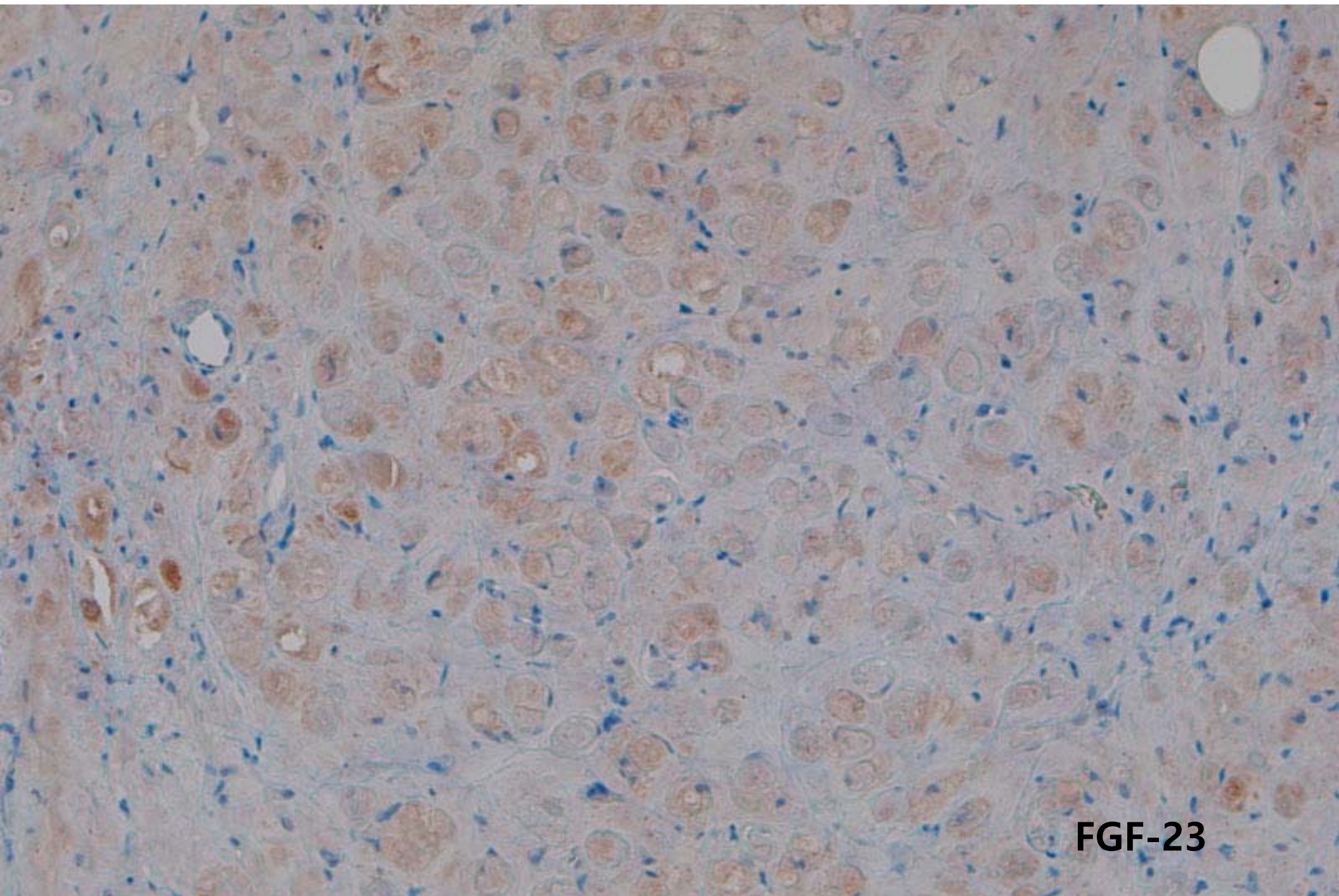




S 04-0015506







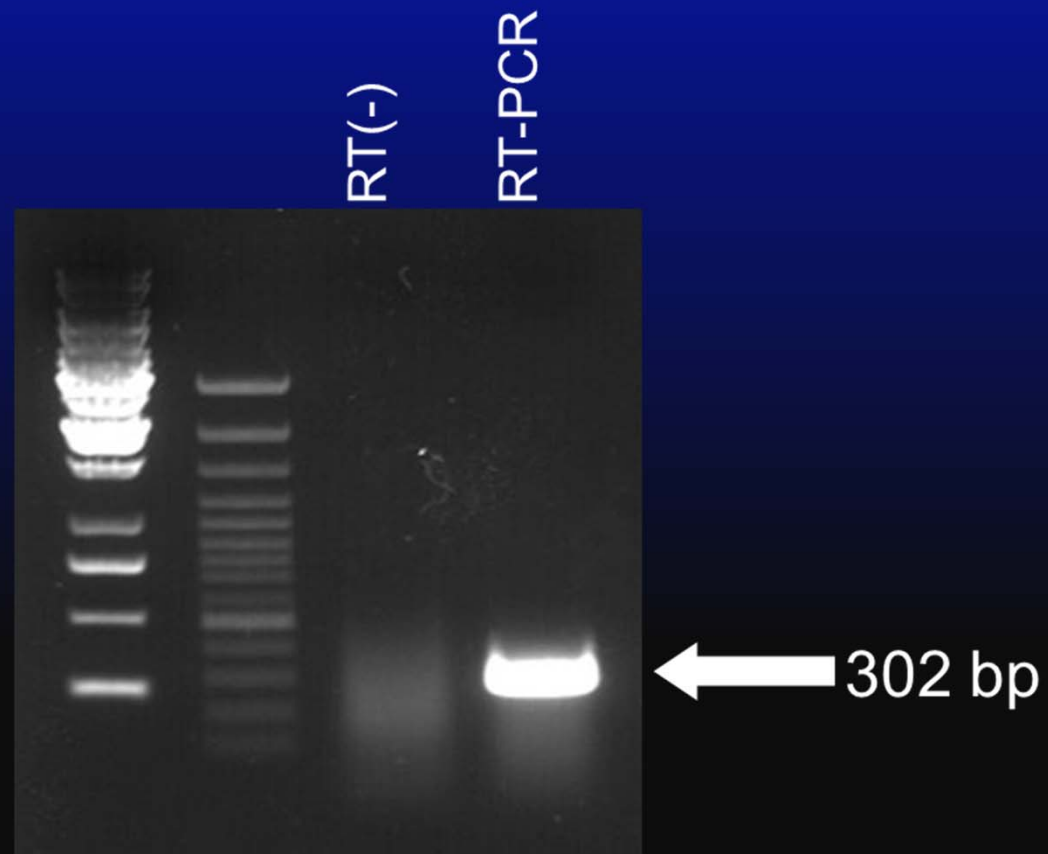
FGF-23

RT-PCR for FGF23 from tumor tissue

Primers :

Sense : 5'-TGGCCAGTGACCCATTAGGG-3'

Antisense : 5'-TGAGGAAGGCGGTGAAACCC-3'

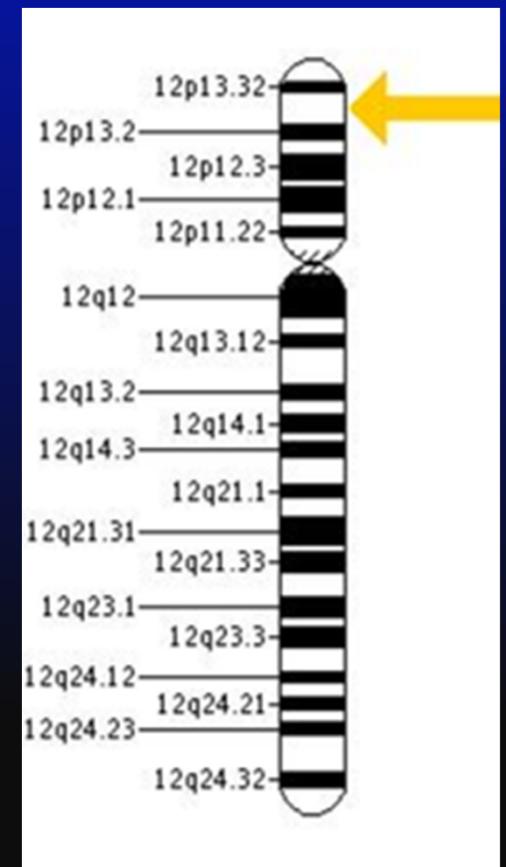

Fibroblast Growth Factor 23

- Phosphatonin–phosphaturic substance
- Highly expressed in Oncogenic osteomalacia, but low levels in normal tissue.

- Reduce serum phosphate & increase fractional excretion of phosphorus

- Resides on human chromosome 12p13 (mouse chromosome 6)



Fibroblast Growth Factor 23

- Autosomal dominant hypophosphatemic rickets (ADHR) is associated with mutation in FGF-23

The ADHR Consortium. Nat Genet 2000

- Identification of FGF-23, preferentially expressed in mouse ventrolateral thalamic nucleus of the brain.

Yamashita T et al. BBRC 2000

- Cloning of FGF23 as a causative factor of oncogenic osteomalacia

Shimada T et al. PNAS 2001

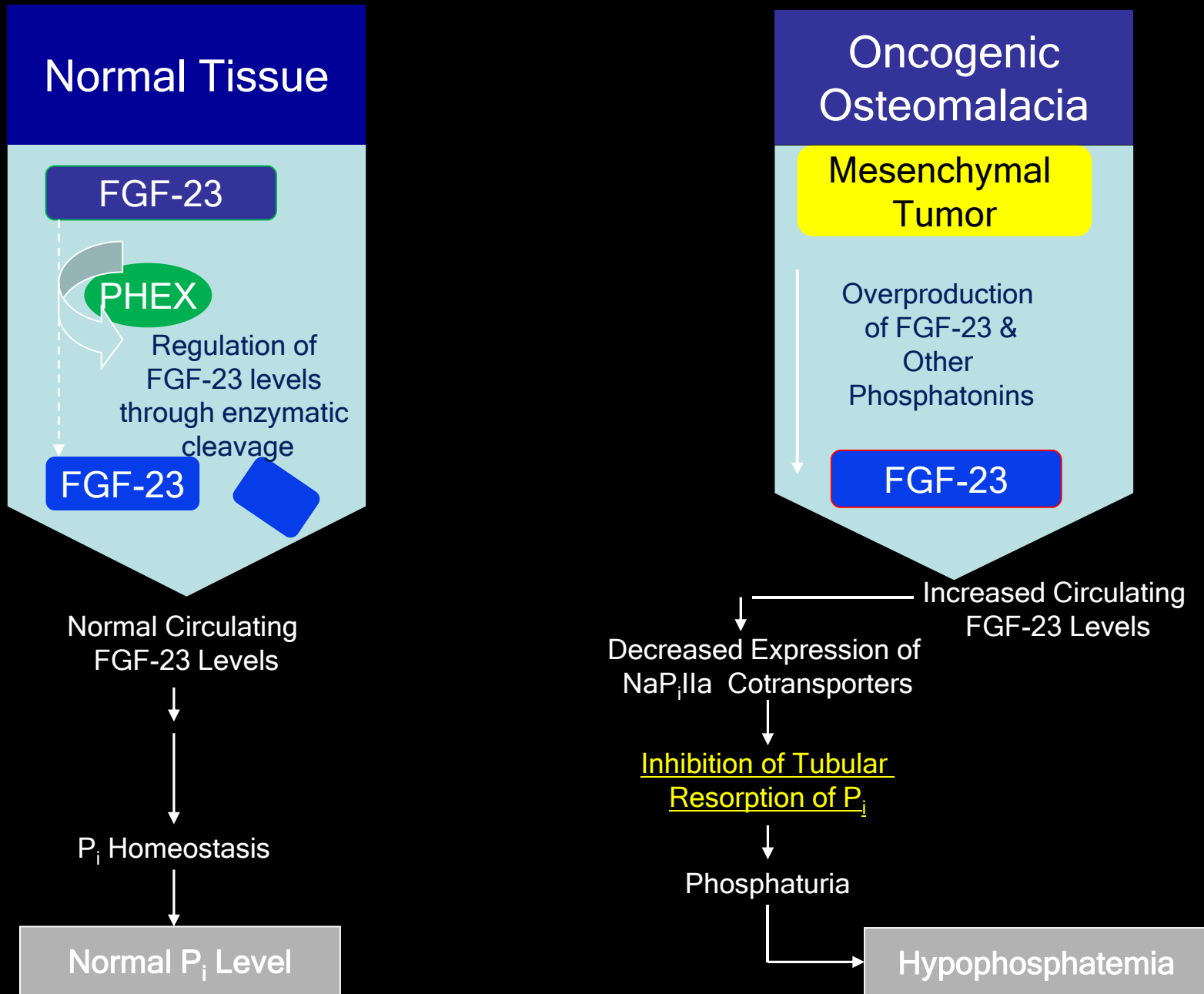
FGF-23 in HypoP rickets/osteomalacia

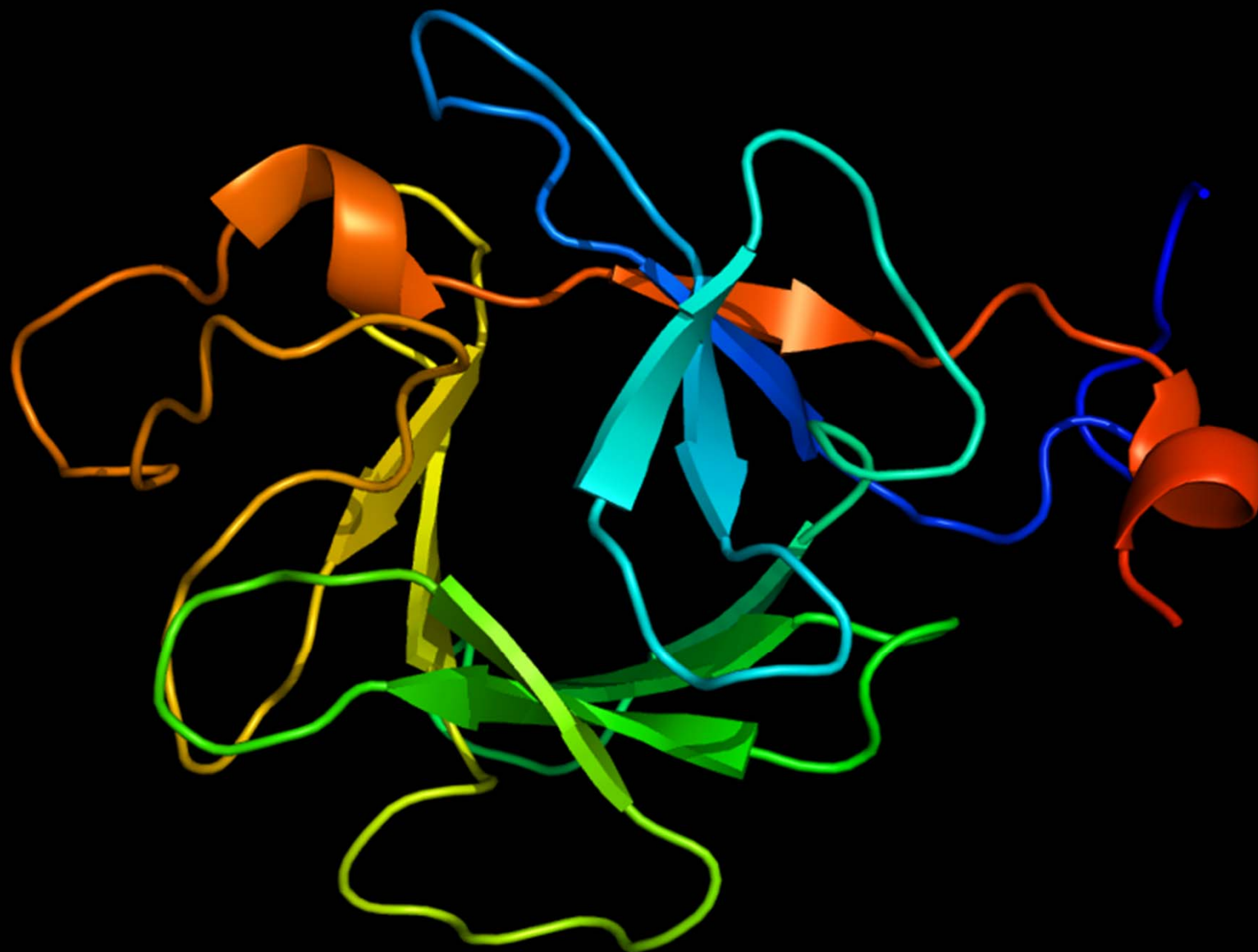
- FGF-23 is overexpressed in tumors responsible for oncogenic osteomalacia (OOM)

White KE, 2001; Shimada T, 2001; Larsson T, 2003

- Elevation of circulating FGF-23 in OOM and XLH patients.

Jonsson KB, 2003; Yamazaki Y, 2002





Araujo–Park projects



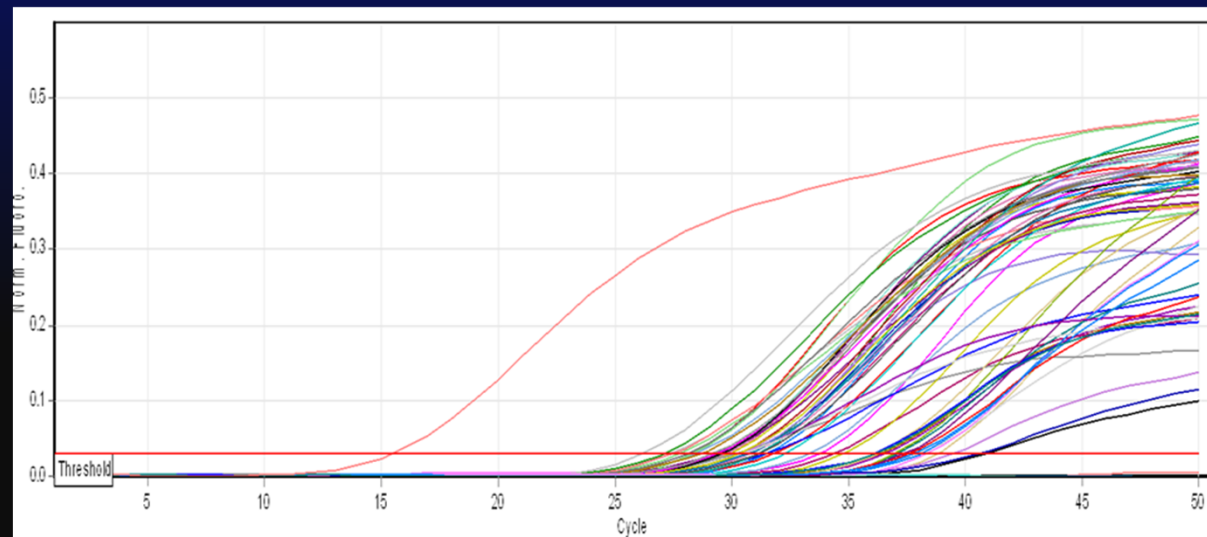
- 137 cases of Giant cell tumors from Seoul Korea and Buenos Aires, Argentina
- FFPE blocks
- (1) RNA isolation
- (2) cDNA generation
- (3) Real time PCR

FGF23 Primers

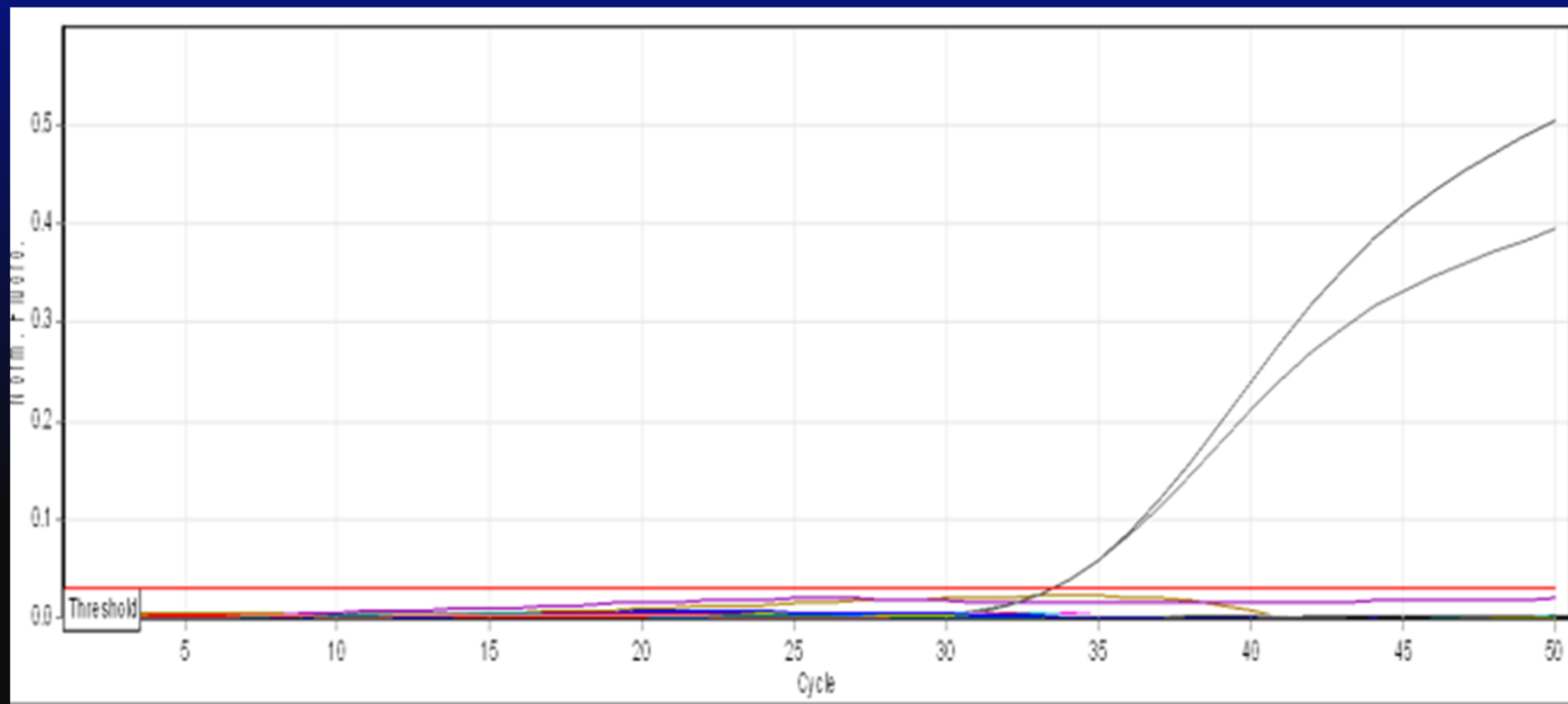
	primer	Length	Sequence	Size(bp)	reference
1	5'	19	5'-GTG GCC TGA TCC ACC TGT A-3'	138	Seoul
	3'	20	5'-CAAAGC CAG CAT CCT CTG AT-3'		
2	5'	21	5'-GGC CTG ATC CAC CTG TAC ACA-3'	140	<i>Mayo, 2009</i>
	3'	21	5'-AAC ACA AAG CCA GCA TCC TCT-3'		
3	5'	21	5'-ACA CAG CCA CAG CCA GGA ACA-3'	125	<i>Mayo, 2009</i>
	3'	21	5'-CAC CAC AAA GCC AGC ATC CTC-3'		
4	5'	20	5'CAC CTG CAG ATC CAC AAG AA-3'	175	<i>Mayo, 2009</i>
	3'	21	5'GGT CGA AAT AGT GTG ATC CAA3'		

Results

- Low yield RNA isolation:
- RNA <10ng/ul: 50/137 cases (36.5 %).
- Real time PCR
GAPDH: 114/137 cases (83.2 %); amplified.
23 cases (16.8 %): low RNA conc. or degradation

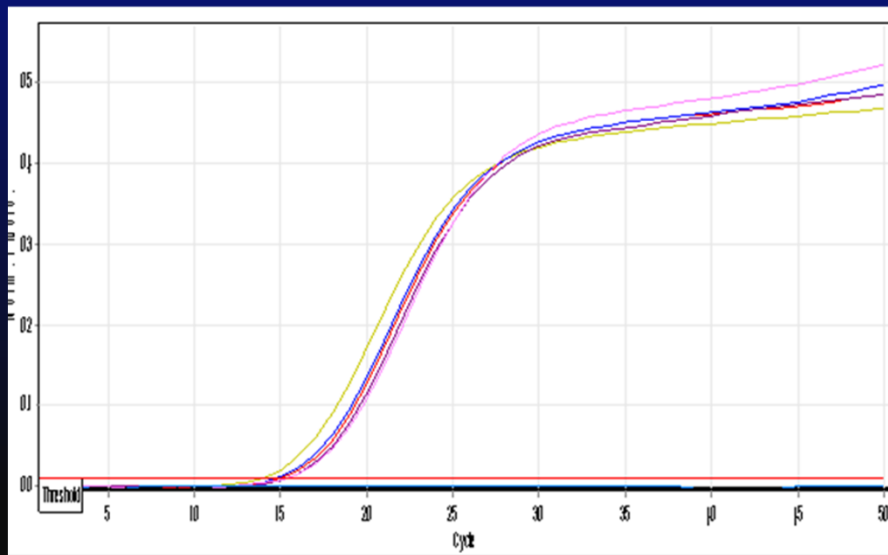


- FGF-23
- Only 2 cases: FGF 23 positive (Seoul primer set; positive, Mayo primer sets; negative)

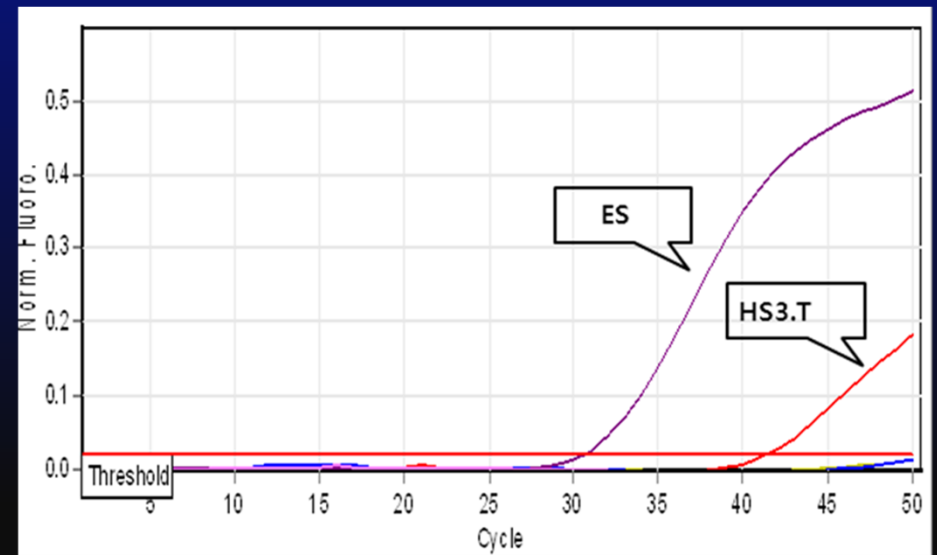


Osteosarcoma cell lines

- ES, HS3.T, MG63, SJSA-1: 4 cell lines
- Same primer sets used.



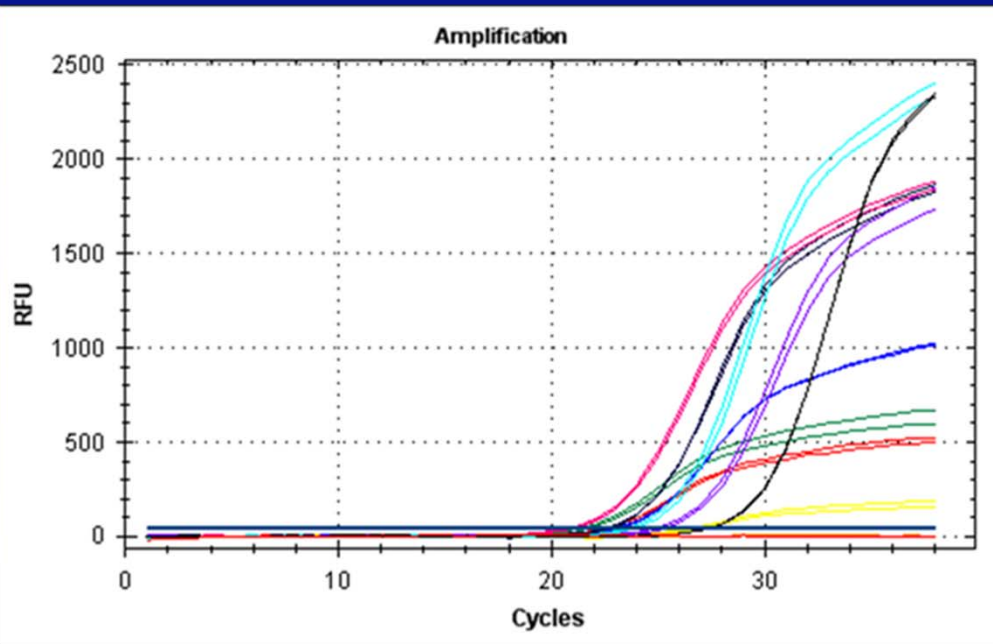
GAPDH



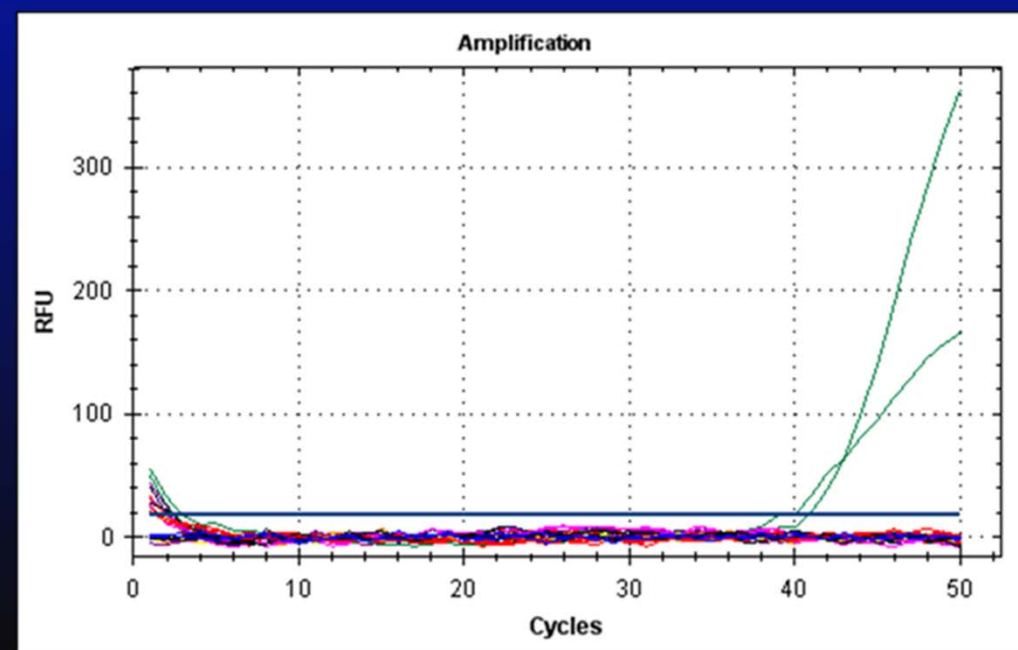
FGF23

Osteosarcoma cases

- 8 Cases: Biopsy prechemotherapy



GAPDH



FGF23

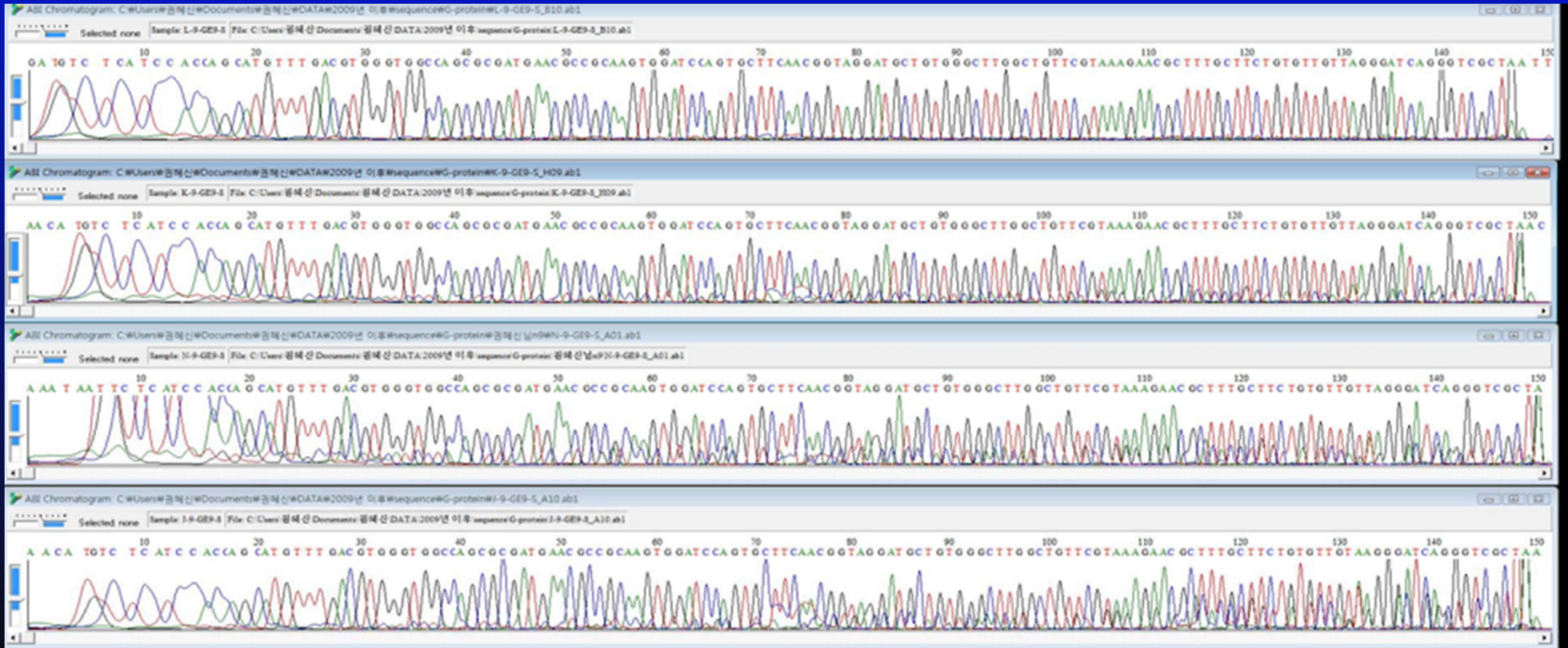G-protein mutation analysis

PCR method, sequencing


- Primer design: Exon 8,9,5-6, *JCEM(1998)*

1	GE8-S	CAG AAA CCA TGA TCT CTG TTA	21	50n	PAGE
2	GE8-AS	TCG GTT GGC TTT GGT GAG ATC CAT	24	50n	PAGE
3	GE9-S	AAC TGC AGC CAG TCC CTC TGG AAT AAC CAG G	31	50n	PAGE
4	GE9-AS	CAG CGA CCC TGA TCC CTA ACA	21	50n	PAGE
5	GE56-S	CCC AGC TAC CTG AAC GAC CTG G	22	50n	PAGE
6	GE56-AS	GCT CAC TTG AAG TGT AGG TC	20	50n	PAGE

EXON 9



Unpublished data, 2018



شكراً جزيلاً

서울의 사랑